

● *Review*

LIVER ULTRASOUND ELASTOGRAPHY: AN UPDATE TO THE WORLD FEDERATION FOR ULTRASOUND IN MEDICINE AND BIOLOGY GUIDELINES AND RECOMMENDATIONS

GIOVANNA FERRAIOLI,^{*} VINCENT WAI-SUN WONG,[†] LAURENT CASTERA,[‡] ANNALISA BERZIGOTTI,[§]
IOAN SPOREA,[¶] CHRISTOPH F DIETRICH,^{||} BYUNG IHN CHOI,[#] STEPHANIE R. WILSON,^{**}
MASATOSHI KUDO,^{††} and RICHARD G. BARR^{‡‡}

^{*} Ultrasound Unit, Department of Clinical Sciences and Infectious Diseases, Fondazione IRCCS Policlinico San Matteo, School of Medicine, University of Pavia, Pavia, Italy; [†] Department of Medicine and Therapeutics, Chinese University of Hong Kong, Hong Kong; [‡] Service d'Hépatologie, Hôpital Beaujon, Clichy, Assistance Publique-Hôpitaux de Paris, INSERM UMR 1149 CRI, Université Denis Diderot Paris-VII, Paris, France; [§] Swiss Liver Center, Hepatology, University Clinic for Visceral Surgery and Medicine, Inselspital, University of Bern, Switzerland; [¶] Department of Gastroenterology and Hepatology, University of Medicine and Pharmacy, Timisoara, Romania; ^{||} Medizinische Klinik 2, Caritas-Krankenhaus, Bad Mergentheim, Germany; [#] Department of Radiology, Seoul National University Hospital, Seoul, South Korea; ^{**} Department of Diagnostic Imaging, Foothills Medical Centre, University of Calgary, Calgary, Alberta, Canada; ^{††} Department of Gastroenterology and Hepatology, Kindai University School of Medicine, Osaka Sayama, Japan; and ^{‡‡} Department of Radiology, Northeastern Ohio Medical University and Southwoods Imaging, Youngstown, Ohio, USA

(Received 1 May 2018; revised 2 July 2018; in final form 13 July 2018)

Abstract—The World Federation for Ultrasound in Medicine and Biology has produced these guidelines for the use of elastography techniques in liver diseases. For each available technique, the reproducibility, results and limitations are analyzed, and recommendations are given. This set of guidelines updates the first version, published in 2015. Since the prior guidelines, there have been several advances in technology. The recommendations are based on the international published literature, and the strength of each recommendation is judged according to the Oxford Centre for Evidence-Based Medicine. The document has a clinical perspective and is aimed at assessing the usefulness of elastography in the management of liver diseases. (E-mail: rgbarr@zoominternet.net) © 2018 The Author(s). Published by Elsevier Inc. on behalf of World Federation for Ultrasound in Medicine & Biology. This is an open access article under the CC BY-NC-ND license. (<http://creativecommons.org/licenses/by-nc-nd/4.0/>).

Key Words: World Federation for Ultrasound in Medicine and Biology guidelines, Liver diseases, Elastography, Transient elastography, Acoustic radiation force impulse, Shear wave elastography, Strain elastography, Liver, Ultrasound, Liver fibrosis, Liver stiffness, Focal liver lesions, Portal hypertension.

INTRODUCTION

Elastography has been used to evaluate liver stiffness for more than 10 y. As chronic liver damage results in hepatic fibrosis, characterized by an increase of extracellular matrix produced by fibroblast-like cells, the liver becomes stiffer than normal. Elastography can be used to assess liver stiffness non-invasively. It measures tissue behavior when an external mechanical actuation or

an internal acoustic radiation force is applied and can be monitored by ultrasound (US) or magnetic resonance imaging (MRI).

This document reviews the several US-based elastography techniques available clinically. Magnetic resonance elastography is not discussed but is described elsewhere (Barr et al. 2016b). The several US-based elastography techniques have been extensively described in Part 1 (Shiina et al. 2015). These techniques differ in the physical approaches used and can be grouped into three major types: (i) transient elastography (TE), which uses a mechanical external push; (ii) acoustic radiation force impulse (ARFI) techniques, which use an acoustic

Address correspondence to: Richard G. Barr, Department of Radiology, Northeastern Ohio Medical University Southwoods Imaging, 7623 Market Street, Youngstown, OH 44512, USA. E-mail: rgbarr@zoominternet.net

internal push; and (iii) strain elastography (SE) technique, which uses frame-to-frame differences (tissue deformation) with stress, caused by pressing the body surface or by internally occurring physiologic motion. The ARFI techniques can be divided into point shear wave elastography (p-SWE) and 2-D shear wave elastography (2-D SWE) techniques. The shear wave-based techniques (TE and ARFI techniques) measure the speed of shear waves in tissues. The shear waves are generated by an external mechanical push in TE or by the push pulse of a focused ultrasound beam in the ARFI techniques. For both of these techniques, the shear wave speed calculated, which is related to liver stiffness, can be converted into kilopascals, the unit of Young's modulus E ($3\rho v^2$, where ρ is the tissue density and v is the speed of the shear wave), assuming that the tissue is purely elastic, incompressible, its elastic response is linear and that the tissue density is always 1000 kg/m^3 . It is important to note that magnetic resonance elastography (MRE) reports the shear modulus in kilopascals and is three times smaller than the Young's modulus used to report the results of the ultrasound techniques (Barr et al. 2016b).

Guidelines on the use of US elastography for the assessment of liver diseases were produced by the World Federation for Ultrasound in Medicine and Biology (WFUMB) a few years ago (Ferraioli et al. 2015); however, this is a very rapid growing field and new evidence and improvements are available since that release.

Our objectives were to determine, based on the evidence from the literature, what is new since the previous release of the WFUMB guidelines (Ferraioli et al. 2015), regarding the impact of elastography on reduced use and/or replacement of liver biopsy for diffuse liver diseases. The potential role of elastography in the characterization of focal liver lesions is also discussed.

The authors met in Chicago in December 2017 to discuss and reach consensus on the use of liver elastography for liver stiffness measurements. Recommendations were made and graded using the Oxford classification, including Level of Evidence (LoE), Grade of Recommendation (GoR) and proportion of agreement (Oxford Centre for Evidence-Based Medicine [OCEBM] 2009).

Terminology, techniques, systems

Transient elastography. Transient elastography is a 1-D technique performed with the FibroScan system (Echosens, Paris, France). The technique has been fully described (Ferraioli et al. 2015).

The newer version of TE, available on the FibroScan 502 Touch system, allows measurement of the decrease in amplitude of ultrasound signal in the liver, using the controlled attenuation parameter (CAP) tool.

The CAP results are given in decibels per meter (dB/m), range from 100 to 400 and are related to the amount of fat in the liver. The system has three types of probes with different ultrasound frequencies. The M probe has an ultrasound frequency of 3.5 MHz for measurement at a depth from 2.5 to 6.5 cm from the skin. The XL probe, with an ultrasound frequency of 2.5 MHz for measurement from 3.5 to 7.5 cm, is used when the skin-to-liver capsule distance is >2.5 cm. The software of the system controls the choice between the two probes based on this distance. The S probe, with an ultrasound frequency of 5.0 MHz for measurements between 1.5 and 5.0 cm, is usually used in children, when the thoracic diameter is <75 cm. As of today, CAP is available on the M and XL probes and is displayed only when the liver stiffness measurement (LSM) is valid, because it is computed from the ultrasound signals used for acquiring LSM (Berzigotti et al. 2018).

Acoustic radiation force impulse techniques. These techniques are based on the generation of shear waves by the push pulse of the ultrasound beam. To generate the tissue displacement, the length of pulse of the US beam is longer than that used for the B-mode image, to provide momentum transfer pushes. The techniques are described in detail elsewhere (Shiina et al. 2015).

The European Federation of Societies for Ultrasound in Medicine and Biology (EFSUMB) has recently updated the guidelines for the use of elastography in the assessment of liver fibrosis (Dietrich et al. 2017a). We agree with that terminology.

Acoustic radiation force impulse-based techniques are available on both the linear and the curvilinear transducers. For assessment of the liver, generally the curvilinear transducer is used (at least in adults). Note that shear wave speeds are dependent on ARFI pulse frequency; therefore, the values will differ if a linear higher-frequency probe is used. Manufacturers have provided quality factors for the measurements (Table 1). These quality factors evaluate if the stiffness value reported meets criteria for an accurate measurement.

VARIABILITY BETWEEN P-SWE AND 2-D SWE SYSTEMS

Limitations and system differences

The main limitation of these techniques is that different estimates of shear wave speed (SWS) are obtained with different systems.

The Quantitative Imaging Biomarker Alliance (QIBA) committee of the Radiologic Society of North America (RSNA) performed an inter-laboratory study of SWS estimation in elastic phantoms. Commercially available SWE systems were used. A statistically

Table 1. Available equipment

SWE technique	System (manufacturer)	Software registered name	Quality criteria and/or additional features (manufacturer derived)	Additional tools
Transient elastography	FibroScan FibroScan 502 Touch (EchoSens, France)	FibroScan	The software determines automatically whether each measurement is successful or not and controls choice between M+ and XL+ probes based on skin-to-liver capsule distance (this second option is available with the newer systems); 10 measurements and $IQR/M \leq 30\%$	Controlled Attenuation Parameter (CAP) to detect and quantify liver steatosis.
Point SWE (pSWE)	Acuson S2000 and 3000 (Siemens Healthineers, Germany)	Virtual Touch Quantification (VTQ)	If signal/to noise ratio is low, “XXX” is displayed.	Combinational elastography (available on the Arietta 850) that combines strain and shear wave elastography. ATT – attenuation software for quantification of liver steatosis.
	iU22, Epiq series, Affiniti (Philips Healthcare, Netherlands)	ElastPQ	No measurement displayed if signal/to noise ratio is low; for each measurement the standard deviation is provided	
	HI-VISION Ascendus, Arietta 70, Arietta 850 (Hitachi Ltd, Japan)	Shear wave measurement (SWM)	No measurement displayed if signal/to noise ratio is low; net amount of effective shear wave velocity (VsN) $\geq 50\%$	
	MyLab 9 (Esaote, Italy)	QElaXto	No measurement displayed if signal/to noise ratio is low; rate of effective measure for each value shown in the screen (H,M,L) Reliable measurement index (RMI)	
2-D SWE	HS70 A, RS80 A (Samsung Medison, South Korea)	S-shearwave	Reliable measurement index (RMI)	Shear wave dispersion imaging, related to tissue viscosity. Attenuation Imaging (ATI) to detect and quantify liver steatosis.
	Aixplorer (SuperSonic Imagine, France)	SSI	No color displayed if signal/to noise ratio is low; stability index (SI)	
	Epiq series (Philips Healthcare, Netherlands)	ElastQ	No color displayed if signal/to noise ratio is low; confidence map	
	Acuson S3000 (Siemens Healthineers, Germany) Logiq E9 (GE Healthcare, USA)	Virtual Touch IQ	Pixels remain blank if result is not “satisfactory”	
	Aplio 500, i-series (Canon Medical Systems, Japan)		Propagation map	
	Resona series, DC-80 system (Mindray, China)	Sound Touch Elastography (STE), Sound Touch Quantification (STQ)	Reliability map (RLB); stability from motion in a period of time frames (M-STB)	

SWE = shear wave elastography

significant difference in SWS estimates among systems and a depth-dependent estimate of SWS for each system were obtained. The inter-system variability ranged from 6% to 12%. No statistically significant differences were found among raters using the same system. The study also reported very good agreement between systems (Hall 2013).

It was found that in viscoelastic phantoms, the deepest focal depth (7.0 cm) yielded the greatest inter-system variability for each phantom (maximum of 17.7%) as evaluated by the interquartile range (IQR), and the median SWS estimates for the greatest outlier system for each phantom/focal depth combination ranged from 12.7% to 17.6% (Palmeri 2015).

A study has evaluated the variability of SWS assessed with a p-SWE technique at various depths using different frequencies. In both the phantom and liver, the mean velocities as measured by two probes at the same depth and at different depths differed. The lowest variability in the phantom was at 4 and 5 cm from surface with the convex probe and at 2 cm with a linear probe. In the liver, the depth with lower variability was 4 cm from the skin with a convex probe and at 3 and 4 cm with a linear probe (Chang et al. 2013). In another study on 89 chronic hepatitis C virus (HCV)-infected patients, the linear probe gave SWS values higher than those obtained with the convex probe (Potthoff et al. 2013). This is expected because the SWS is dependent on the ARFI frequency: The higher the ARFI frequency, the higher the SWS.

A recent study has evaluated the inter-system and inter-observer variability of LSMs in patients with varying degrees of liver stiffness (Ferraioli et al. 2018). The assessment of LSMs was performed using six US systems, four with p-SWE and two with 2-D SWE. The Fibroscan was used as the reference standard. There was an agreement >0.80 for all pairs of systems. The mean difference between the values of the systems with 2-D SWE technique was 1.54 kPa, whereas the maximum mean difference between the values of three of four systems with p-SWE technique was 0.79 kPa. The variability between measurements obtained with different systems was higher in stiffer liver. The range of values obtained with the two 2-D SWE systems paralleled that of the Fibroscan in cases of very stiff liver (>15 kPa), whereas the four systems with a p-SWE technology gave lower values in the higher range of liver stiffness. The intra-patient concordance for all systems was 0.89 (95% confidence interval [CI]: 0.83–0.94). Inter-observer agreement was >0.90 .

Piscaglia et al. (2017) reported that the correlation between stiffness measurements taken with several systems (including the Fibroscan) in different intercostal spaces was good but not perfect.

Table 2. Recommendations for performing liver elastography

Adherence to a strict protocol is required.
Patient should fast for 4 h before examination.
Exam should be performed with the patient in the supine or slight left lateral position with the arm raised above the head to increase the intercostal space.
Measurements should be taken through an intercostal approach at the location of the best acoustical window.
Measurements should be taken 1.5 to 2.0 cm below the liver capsule to avoid reverberation artifact. The optimal location for maximum shear wave generation is 4.0–4.5 cm from the transducer.
The transducer should be perpendicular to the liver capsule.
Placement of the region of interests should avoid large blood vessels, bile ducts and masses.
For transient elastography, the appropriate transducer should be selected based on patient's body habitus.
Ten measurements should be obtained from 10 independent images, in the same location, with the median value used for transient elastography and point shear wave elastography techniques. Three or five measurements may be appropriate for 2-D shear wave elastography when a quality assessment parameter is used.
The IQR/M (interquartile range/median) should be used as a measure of quality. For kPa measurements the IQR/M should be <0.3 and for m/s it should be <0.15 for an accurate data set.

Recommendation 1: Cutoffs for staging liver fibrosis are system specific. (LoE 1b, GoR A) (10,0,0)

TECHNICAL PROCEDURES

For all SWE techniques, adherence to a strict protocol is required (Table 2) (Barr et al. 2016b). Patients should be fasting for at least 4 h, as ingestion of food increases blood flow to the liver, increasing its stiffness (Barr et al. 2016b). Ingestion of food can only increase the liver stiffness, therefore, if patients eat and their stiffness values are normal, they have no or mild fibrosis.

TRANSIENT ELASTOGRAPHY

The procedure has been fully described in the previous WFUMB guidelines on liver elastography (Ferraioli et al. 2015). The strengths of the TE approach are that it is widely available and a point-of-care technique. Weaknesses are the lack of gray-scale image guidance to determine where the measurement is being obtained, inability to visualize and avoid large vessels and masses at the site of measurement (although these may be generally identified on the time-motion and A-mode), the need for recalibration of the spring in the device at 6- to 12-mo intervals (depending on the type of probe), decreased applicability in cases of obesity and inability to use it in patients with ascites.

ARFI-BASED TECHNIQUES

The procedure has been fully described in the previous guidelines (Barr et al. 2016b). These are listed in Table 2.

Although most vendors allow measurements to 8 cm from the transducer, measurement accuracy decreases below 6 cm from the transducer because of attenuation of the ARFI pulse.

The literature suggests that 10 measurements should be obtained for *p*-SWE, and the median value reported. Several studies have indicated that an IQR/median (M) $\leq 30\%$ (measurements in kPa) improves accuracy in staging liver fibrosis. Recent literature suggests that a smaller number of measurements may be accurate (Fang *et al.* 2018; Ferraioli *et al.* 2016a); however, at this time there is not enough literature to support this suggestion. The energy deposition of the ARFI push pulse for U.S. Food and Drug Administration (FDA)-approved vendor systems is within current FDA diagnostic limits for livers in adults. Off-label use for other organs and for use during and immediately after the use of US contrast materials should be avoided until further investigated (Cui *et al.* 2014).

In 2-D SWE, a larger field of view (FOV) is placed where the elastogram will be obtained. Within that FOV, regions of interest (ROIs) can be placed to obtain the stiffness value. As opposed to *p*-SWE, the ROI size can be changed. If possible, the ROI should be placed near the center of the FOV, as there are often errors at the borders of the FOV. Most vendors provide the average and the standard deviation of the stiffness values from the pixels in the ROI, and some of them provide the minimum and maximum stiffness values as well. The mean value should be used. The standard deviation within the ROI reports the variability of the pixel measurements within the ROI and is not a measure of the quality of the measurement.

Not enough studies have been performed to provide recommendations, but several studies using 2-D SWE have used three or five measurements if the system has a quality measure that confirms the area of measurement has high-quality shear waves (Dietrich *et al.* 2017a). Most vendors with 2-D SWE may allow the placement of many ROIs within the elastogram FOV. This is discouraged, because if there is an error in that image, the error is reproduced in all the measurements from that image.

STRAIN ELASTOGRAPHY

There is no significant change from previous WFUMB liver elastography guidelines (Table 2) (Ferraioli *et al.* 2015).

A limited study using combinational elastography, the combined use of strain and shear wave imaging with a single machine, might increase accuracy in the diagnosis of liver fibrosis and inflammation (Yada *et al.* 2017a, 2017b). Data mining, which combines

SE and serologic tests, is reported to be the novel approach (Yada *et al.* 2014). In a meta-analysis (Kobayashi *et al.* 2015) of 15 studies with 1626 patients, SE was found not to have high accuracy for any cutoff stage of fibrosis.

REPRODUCIBILITY

Shear wave elastography techniques have excellent reproducibility, provided the recommendations of the manufacturer or expert recommendations are followed. For all systems, intra-observer reproducibility assessed with the intra-class correlation coefficient (ICC) was >0.90 , and inter-observer reproducibility was >0.80 (Boursier *et al.* 2008a; Fang *et al.* 2017; Ferraioli *et al.* 2012; Fraquelli *et al.* 2007; Garcovich *et al.* 2017; Hudson *et al.* 2013).

Factors that influence the reproducibility of the measurement are similar across the different techniques and are related to the operator's experience and to factors dependent on the subject being examined. A learning curve has been consistently observed not only for TE (Boursier *et al.* 2008b), but also for *p*-SWE (Fraquelli *et al.* 2016) and 2-D SWE (Ferraioli *et al.* 2012; Hudson *et al.* 2013; Woo *et al.* 2015), with higher reproducibility achieved by expert operators.

Inter-observer variability increases with higher liver fibrosis stages (Boursier *et al.* 2008a; Fraquelli *et al.* 2007; Vuppalachchi *et al.* 2018) and in overweight or obese patients (Boursier *et al.* 2008a; Fraquelli *et al.* 2007). Patient position and respiration phase can affect the results, and variability is decreased by using standardization.

CONFOUNDING FACTORS AND LIMITATIONS

Although liver fibrosis is the main determinant of liver stiffness, a number of factors have been found to influence LSM, often resulting in a false-positive diagnosis of advanced fibrosis or cirrhosis. Clinicians should be aware of these confounding factors and avoid using liver elastography in such situations. Although most of the studies were conducted using TE for historical reasons, studies using *p*-SWE or 2-D SWE almost always produced similar effects, suggesting that the same confounders should affect all techniques similarly. Confounding factors were already reported in the previous guidelines (Barr *et al.* 2016b; Dietrich *et al.* 2017a; Ferraioli *et al.* 2015). Details on the published studies are available in Supplement 1 (online only). Liver steatosis causes attenuation of the ARFI pulse and can lead to more variability in the measurements, although theoretically it should not affect the SWS, based on current ARFI methods in clinical use, even though some reports have indicated that livers with steatosis have increased

viscoelasticity, which can also affect SWS. Published studies have conflicting results.

RECOMMENDATION 2: The impact of hepatic steatosis on liver stiffness is uncertain. Clinicians should exercise caution when interpreting liver stiffness results in patients with severe steatosis and obesity. (LoE 5, GoR C) (10,0,0)

VIRAL HEPATITIS

Hepatitis B

The performance of transient elastography in chronic hepatitis B was described in the last WFUMB guidelines (Ferraioli et al. 2015). Since then, 2-D SWE (Leung et al. 2013; Zeng et al. 2017) and p-SWE (Hu et al. 2017; Kim et al. 2016; Su et al. 2018) have also been evaluated against liver histology in patients with chronic hepatitis B. Overall, studies have indicated similar diagnostic accuracy across different machines. The accuracy is generally good for the diagnosis of bridging fibrosis and cirrhosis, and it is modest for milder degrees of fibrosis. Two-dimensional SWE and p-SWE also have lower failure rates, especially among obese patients. As currently available antiviral drugs are tolerable and efficacious, the decision to start antiviral therapy can in most cases be made based on serum alanine aminotransferase and hepatitis B virus DNA levels, as well as non-invasive tests of fibrosis (European Association for the Study of the Liver [EASL] 2017; Terrault et al. 2018). Patients with liver stiffness values suggestive of cirrhosis would need surveillance for hepatocellular carcinoma and varices. Liver biopsy is now rarely required outside the research setting.

A high serum alanine aminotransferase (ALT) level is one of the major confounding factors for liver stiffness measurement (see Supplement 1 for details). Even patients with mild to moderate ALT elevation to one to five times the upper limit of normal have higher liver stiffness than those with normal ALT levels (Chan et al. 2009). Oral nucleos(t)ide analogues effectively suppress hepatic necroinflammation and lead to ALT normalization in the majority of patients with chronic hepatitis B (Wong et al. 2009). Studies have consistently found that patients can have a significant reduction in liver stiffness during nucleos(t)ide analogue treatment even when there is little or no improvement in histologic fibrosis (Liang et al. 2018; Wong et al. 2011). The optimal cutoffs for fibrosis and cirrhosis in treated patients are likely to be lower than those in untreated patients, but need to be defined in future studies. In addition, although long-term nucleos(t)ide analogue treatment can reverse histologic cirrhosis (Marcellin et al. 2013), the risk of hepatocellular carcinoma in such patients

is still higher than in those who never had cirrhosis (Wong et al. 2013). On the other hand, worsening of portal hypertension and new development of varices should be uncommon during nucleos(t)ide analogue treatment, though the experience is limited to small-cohort studies (Lampertico et al. 2015). Until further data are available, it is premature to recommend a change in surveillance strategies in cirrhotic patients treated with nucleos(t)ide analogues based on changes in liver stiffness.

RECOMMENDATION 3: SWE is useful to exclude significant fibrosis and diagnose cirrhosis in patients with untreated chronic hepatitis B. (LoE 1a, GoR A) (10,0,0)

RECOMMENDATION 4: Liver stiffness usually decreases during antiviral treatment with analogues. Screening for hepatocellular carcinoma and portal hypertension should continue despite decrease liver stiffness in patients with advanced disease (LoE 1b, GoR A) (10,0,0)

Hepatitis C

The current recommendations for treatment of HCV vary significantly between countries and health care systems, according to the availability of therapy. In the absence of universal access to direct-acting antiviral agents (DAAs), as a consequence of high cost, different countries have implemented strategies to prioritize patients for treatment based on disease stage. In that respect, SWE can be used as the first-line investigation for the prioritization of HCV patients for DAAs (Dietrich et al. 2017b; EASL 2015a, 2015b; EASL–ALEH 2015). The most important endpoint is the presence of cirrhosis as these patients are still at risk (although much lower) of developing liver-related complications, such as portal hypertension and hepatocellular carcinoma (HCC) (Di Marco et al. 2016; Nahon et al. 2017; van der Meer et al. 2017; Yada et al. 2016), after HCV eradication. Thus, they require regular follow-up.

RECOMMENDATION 5: SWE is the preferred method as the first-line assessment for the severity of liver fibrosis in untreated patients with chronic viral hepatitis C. It is useful to rule out advanced disease. (LoE 1a, GoR A) (10,0,0)

Role of elastography during antiviral treatment (monitoring)

Most data available on the usefulness of liver stiffness monitoring during antiviral therapy have been obtained with TE. Monitoring of liver stiffness during antiviral treatment with interferon-based therapies has not been considered clinically meaningful (Hezode et al. 2011; Yada et al. 2014) and has not been recommended by guidelines (Ferraioli et al. 2015). Data in patients

treated with DAAs suggest that liver stiffness rapidly declines during treatment, even in patients with advanced fibrosis and cirrhosis (Chan *et al.* 2018; Faciorusso *et al.* 2018; Knop *et al.* 2016; Ogasawara *et al.* 2018; Persico *et al.* 2018; Pons *et al.* 2017; Sporea *et al.* 2017). This decline appears to reflect the reduction in liver inflammation, like an effect of HCV eradication. However, given the short duration of treatment with DAAs (12 wk) and the high sustained virologic response (SVR) rates (>90%), monitoring of liver stiffness during treatment does not appear clinically relevant.

Role of elastography after treatment (monitoring in follow-up)

Although it is tempting to monitor liver stiffness, in cirrhotic patients after SVR, based on the currently available evidence, liver stiffness decrease cannot be used as a surrogate of cirrhosis regression. Therefore, no recommendation can be made at this stage on cutoffs and the time interval to identify cirrhosis regression.

A detailed discussion is presented in Supplement 2 (online only).

RECOMMENDATION 6: Liver stiffness decreases significantly after sustained virological response to treatment with interferon-based therapies or direct-acting antiviral agents. However, liver stiffness cannot be used to stage liver fibrosis or rule out cirrhosis, given the loss of accuracy of cutoffs defined in viremic patients. Screening for hepatocellular carcinoma and portal hypertension should continue despite decrease in liver stiffness in patients with advanced disease. (LoE 1b, GoR A) (10,0,0)

NON-ALCOHOLIC FATTY LIVER DISEASE/ NON-ALCOHOLIC STEATOHEPATITIS

Non-alcoholic fatty liver disease (NAFLD) is becoming the most common cause of chronic liver disease and a risk factor for HCC (Dyson *et al.* 2014).

Transient elastography

Several studies have reported the performance of TE in the assessment of liver fibrosis in NAFLD patients. A recent large meta-analysis (Xiao *et al.* 2017) has reported that, with the M probe, the cutoff for advanced fibrosis ranged from 7.6 to 9 kPa in 14 studies including 2697 patients, with 83% to 89% sensitivity and 77% to 78% specificity. For the XL probe, the cutoff ranged from 5.7 to 9.3 kPa in three studies including 579 patients, with 75% sensitivity and 74% specificity. In a multicenter study (Petta *et al.* 2015) of NAFLD patients with liver biopsy data, the cutoff values were 6.9 kPa for $F \geq 2$ and 8.4 kPa for $F \geq 3$. In this study, the presence of severe liver steatosis was associated with higher

LSMs in patients with low-grade fibrosis, leading to the overestimation of liver fibrosis. Therefore, in NAFLD patients, severe steatosis could be a confounding factor (Petta *et al.* 2015).

In almost all studies, obesity was the major reason for unreliable LSMs; however, the use of the M probe seems the major limitation, leading to higher LSMs and a higher false-positive rate. This limitation is somewhat overcome by using the XL probe (Friedrich-Rust *et al.* 2010; Wong *et al.* 2010). It has been reported that the XL probe gives cutoff values 1.5–2 kPa lower than that obtained with the M probe. In a study that compared the M and XL probes (Wong *et al.* 2012) on 155 patients, the measurements with M and XL probes correlated well with each other, $r=0.95$, but with the XL probe, the LSMs were lower.

It has therefore been suggested that different cutoff values be used for different probes. For the M probe, with a 90% sensitivity and specificity to rule in or rule out significant fibrosis, advanced fibrosis and cirrhosis, the cutoff values were 5.8 and 9.0 kPa, 7.9 and 9.6 kPa, and 10.3 and 11.5 kPa, respectively (Wong *et al.* 2010). For the XL probe, with a 90% sensitivity and specificity to rule-in or rule-out significant fibrosis, advanced fibrosis and cirrhosis, the cutoff values were 4.8 and 8.2 kPa, 5.7 and 9.3 kPa and 7.2 and 11.0 kPa, respectively (Wong *et al.* 2012).

Point shear wave elastography

Few studies have addressed the value of *p*-SWE for liver fibrosis in NAFLD/non-alcoholic steatohepatitis (NASH) (Cassinotto *et al.* 2013; Fierbinteanu Braticevici *et al.* 2013; Friedrich-Rust *et al.* 2012; Liu *et al.* 2015b; Osaki *et al.* 2010; Yoneda *et al.* 2010). The most recent is a systematic review with meta-analysis, but the article did not provide the optimal cutoff values, and only reported that the *p*-SWE technique had good performance (area under the receiver operating characteristic curve [AUROC] = 0.89, sensitivity = 80%) (Liu *et al.* 2015b).

2-D shear wave elastography

Three studies available in the literature report the performance of 2-D SWE (Cassinotto *et al.* 2016; Herrmann *et al.* 2018; Zheng *et al.* 2015). The most recent is a meta-analysis with individual patient data that proposed a cutoff value for diagnosing significant fibrosis ($F \geq 2$): >7.1 kPa (AUROC = 0.85) (Herrmann *et al.* 2018).

One study compared three elastographic methods (TE, *p*-SWE and 2-D SWE) in NAFLD patients (Cassinotto *et al.* 2014). For significant fibrosis, 2-D SWE was superior to *p*-SWE, and for severe fibrosis and cirrhosis, all methods had similar performance. In a large meta-analysis (Xiao *et al.* 2017), 2-D SWE had higher

diagnostic accuracy than TE and laboratory fibrosis scores in staging fibrosis.

RECOMMENDATION 7: SWE can be used for liver stiffness assessment in NAFLD patients to rule out advanced fibrosis and select patients for further assessment. (LoE 1a, GoR A) (10,0,0)

ALCOHOLIC LIVER DISEASE

Chronic, excessive alcohol consumption can lead to a large spectrum of damage, from liver steatosis to liver cirrhosis (MacSween and Burt 1986). The risk of developing cirrhosis starts with 30 g ethanol/d and increases with increasing daily intake. Also, drinking multiple different alcoholic beverages can increase the risk of developing ALD (Bellentani et al. 1997). Other studies have found that the risk ratio increases significantly with daily consumption of 20–40 g ethanol/d in women and >80 g ethanol/d in men (Stewart and Day 2011; O’Shea et al. 2010).

Assessment of liver fibrosis

It is important to identify patients with advanced fibrosis who are at risk of developing decompensated liver cirrhosis and HCC. Unfortunately, there are few studies published in the literature.

Transient elastography

There are several studies that reported that TE can be used in patients with ALD, with good performance; however, they report different cutoff values (Anastasiou et al. 2010; Bardou-Jacquet et al. 2013; Boursier et al. 2009; de Ledinghen et al. 2012b; Dolman et al. 2013; Janssens et al. 2010; Kim et al. 2009; Lannerstedt et al. 2013; Lemoine et al. 2008; Mueller et al. 2010; Nahon et al. 2008; Nguyen-Khac et al. 2008; Thiele et al. 2016, 2018; Voican et al. 2017). A Cochrane review summarized these studies (Pavlov et al. 2015) and reported that for diagnosing significant fibrosis, the optimal cutoff value were around 7.5 kPa, with 94% sensitivity and 89% specificity. For severe fibrosis, a cutoff value of 9.5 kPa (range: 8–11 kPa) gave 92% sensitivity and 70% specificity. For liver cirrhosis, the optimal cutoff value was 12.5 kPa, with 95% sensitivity and 71% specificity (Pavlov et al. 2016).

Point shear wave elastography

There are three studies in the literature on liver fibrosis assessment with p-SWE. One study (Liu et al. 2015a) reported only that the correlation between p-SWE and liver biopsy is good ($r=0.71$). The other two studies (Kiani et al. 2016; Zhang et al. 2015), in which liver biopsy was also performed, gave different

cutoff values. This may have occurred because the two studies had smaller and different numbers of patients.

2-D shear wave elastography

There are limited studies in the literature on the use of 2-D SWE in ALD (Thiele et al. 2016).

When is the best time to assess liver fibrosis in ALD patients?

Four studies reported that liver stiffness decreases significantly after patients stopped alcohol abuse (Bardou-Jacquet et al. 2013; Gelsi et al. 2011; Mueller et al. 2010; Trabut et al. 2012). Another study found that it is better to scan the patients when they have AST values <100 U/L (Mueller et al. 2015). Measurements are more accurate if performed after a period of abstinence (Bardou-Jacquet et al. 2013; Gianni et al. 2017)

Recommendation 8: SWE can be used for liver stiffness assessment in patients with ALD to rule out advanced disease. Caution is needed in patients with ongoing alcohol abuse or with acute alcoholic hepatitis. (LoE 2a, GoE B) (10,0,0)

OTHER ETIOLOGIES

Autoimmune hepatitis (AIH) is a chronic inflammatory liver disease of unknown origin. Hepatic fibrosis may progress despite immunosuppressive treatment (Manns et al. 2010). Approximately one-third of patients already have established cirrhosis at diagnosis. According to the International Autoimmune Hepatitis Group, the diagnosis of AIH is based on a combination of biochemical, immunologic and histologic features and the exclusion of viral hepatitis (Hennes et al. 2008). No generally accepted characteristic imaging features of AIH have been described.

AIH patients tend to have higher LSM cutoff values using TE (Abdalla et al. 2009; Fitzpatrick et al. 2013; Guo et al. 2017; Sagir et al. 2008; Wang et al. 2011; Xu et al. 2017b), p-SWE (Bota et al. 2013; Efe et al. 2015; Righi et al. 2012) and 2-D SWE (Sun et al. 2016), compared with patients with HCV and other etiologies. This could be explained by concomitant inflammatory activity, which can increase liver stiffness. TE can predict the grade of fibrosis in treated AIH patients (Anastasiou et al. 2016; Hartl et al. 2016; Sporea et al. 2013), with better results after 6 mo than at earlier time points (Hartl et al. 2016).

There is some preliminary evidence suggesting that primary biliary cirrhosis (PBC) and primary sclerosing cholangitis (PSC) have prognostic significance for LSM (Corpechot et al. 2012, 2014).

There is insufficient evidence to make a recommendation on the use of SWE for liver stiffness assessment

in patients with autoimmune, cholestatic and genetic liver diseases.

CIRRHOSIS AND ITS COMPLICATIONS

For the diagnosis of cirrhosis there are no major changes from the previous guidelines (Ferraioli *et al.* 2015). In patients with advanced chronic liver disease/compensated cirrhosis, LSM is significantly and positively correlated with the hepatic venous pressure gradient (HVPG, “gold standard” method for portal hypertension in cirrhosis).

Most data available concern TE. With this technique, LSM and HVPG yield a correlation coefficient of 0.55–0.86 (Berzigotti 2017). Even if an accurate estimation of the HVPG value cannot be achieved using LSM, LSM accurately discriminates between patients with and without clinically significant portal hypertension (CSPH, defined as HVPG ≥ 10 mm Hg, threshold for the appearance of complications); the summary AUROC is 0.93 according to a meta-analysis (You *et al.* 2017). It should be underlined that most of the patients included in the studies that correlated HVPG with LSMs had viral or alcoholic cirrhosis, and evidence regarding other etiologies remains limited. In untreated viral cirrhosis, LSM values >20 – 25 kPa are highly specific for CSPH (You *et al.* 2017). Values of LSM >20 kPa remain associated with the presence of CSPH in patients with HCV-related cirrhosis who achieved SVR with DAAs (Lens *et al.* 2017); importantly, the decrease in LSM to lower values after SVR does not exclude CSPH, and therefore, clinical follow-up should be continued irrespective of the value of LSM in this population (Lens *et al.* 2017).

High LSM values are also significantly associated with the presence and size of gastroesophageal varices, with summary AUROCs of 0.78–0.84 (Berzigotti 2017). Platelet count and spleen size significantly improve the prediction of varices, obtained by LSM alone (Berzigotti *et al.* 2013). It has been reported that compensated patients with values of LSM <20 kPa and normal platelet counts (>150 G/L) bear a very low risk of varices requiring treatment (large varices or varices with red signs) (Abralde *et al.* 2016). These criteria have been recommended by the Baveno VI consensus conference on portal hypertension as a rule, to eliminate unnecessary endoscopies (de Franchis and Baveno 2015). Since the publication of the recommendation, several studies have confirmed that these criteria are safe (0–3% of varices needing treatment are missed), but very conservative, allowing endoscopy to be spared in only 15% to 30% of patients with compensated cirrhosis (Marot *et al.* 2017). Expanded criteria have recently been proposed by a multicentric consortium; an LSM

<25 kPa and platelet count >110 g/L might be used safely, eliminating a larger proportion of endoscopies (32% vs. 14%) (Augustin *et al.* 2017).

Data regarding LSMs by *p*-SWE and 2-D SWE in this field remain limited.

Point SWE has been used in three studies addressing the diagnosis of CSPH (Attia *et al.* 2015; Salzl *et al.* 2014; Takuma *et al.* 2016b) and reporting excellent applicability and very good diagnostic accuracy (AUROC: 0.82–0.90). Point SWE has been used in a few studies addressing the diagnosis and severity of esophageal varices. Liver stiffness was higher in patients with esophageal varices of any size and was even higher in patients with large varices (Attia *et al.* 2015; Salzl *et al.* 2014). However, reliable cutoffs are not available yet. No strong recommendation regarding the cutoffs to be used can be made because of the limited evidence.

Two-dimensional SWE has been tested for the diagnosis of CSPH in four studies and a further small series (Choi *et al.* 2014; Elkrief *et al.* 2015; Jansen *et al.* 2016a; Kim *et al.* 2015; Procopet *et al.* 2015). The accuracy of the method was reliable in all of the published studies (AUROC: 0.80–0.92). Two studies performed a head-to-head comparison between LSMs obtained by TE and 2-D SWE (Elkrief *et al.* 2015; Procopet *et al.* 2015). TE was less applicable, and both techniques had similar accuracy for the diagnosis of CSPH.

In summary, in the available studies, the applicability and diagnostic accuracy of both techniques closely resemble those of TE (for CSPH *p*-SWE: AUROC 0.82–0.90; 2-D SWE: AUROC 0.80–0.92) (Berzigotti 2017). Cutoffs are, however, not yet well defined and vary across studies (*p*SWE: 2.17–2.58 m/s; 2-D SWE: 15.2–24.5 kPa). Similar considerations apply to the diagnosis of varices.

One study compared TE with *p*-SWE (Salzl *et al.* 2014), and two studies concomitantly evaluated TE and 2-D SWE (Elkrief *et al.* 2015; Procopet *et al.* 2015), reporting similar accuracy for the detection of CSPH. Because of the limited evidence to date, non-invasive criteria to rule out varices based on *p*-SWE or 2-D SWE cannot yet be recommended.

Spleen stiffness measurement (SSM) has been proposed as an additional parameter potentially better correlating with portal pressure, irrespective of its cause. Data in cirrhosis are conflicting. A meta-analysis of 16 studies (using either TE, *p*-SWE or 2-D SWE) pointed to the superiority of this method (Ma *et al.* 2016), but the applicability of TE and 2-D SWE in this setting (about 70%) and the heterogeneity of the populations assessed do not allow recommendations on its use in clinical practice. Recent studies using TE found that LS was more accurate than spleen stiffness (SS) for the diagnosis of CSPH (AUROCs of 0.95 vs. 0.85 [Zyklus *et al.* 2015]; 0.78 vs.

0.63 [Elkrief et al. 2015]). Several studies suggested that SS measurement (SSM) using pSWE could better predict the presence of varices and high-risk varices compared with LS. For example, one study including 340 cirrhotic patients and 16 healthy volunteers with invasive endoscopy as the reference standard found that a shear wave velocity cutoff value of 3.30 m/s identified high-risk esophageal varices, with a negative predictive value, sensitivity and accuracy of 0.994, 0.989 and 0.721, respectively (Takuma et al. 2013). In another study, SSM cutoff values of 3.36 and 3.51 m/s identified patients with esophageal varices and high-risk esophageal varices, respectively, with negative predictive values of 96.6% and 97.4%, respectively (Dietrich et al. 2017a). Several additional studies have found SSM to be predictive of esophageal varices (Sigrist et al. 2017). LSMs obtained with 2-D SWE are higher in patients with esophageal varices of any size and are further increased in patients with large varices. However, reliable cutoff values are not available yet. No strong recommendation regarding the cutoff values for 2-D SWE can be given, and further evidence is needed.

Sequential LSMs and SSMs using 2-D SWE have been recently proposed to improve the selection of patients requiring endoscopy (Jansen et al. 2016b).

RECOMMENDATION 9: SWE has high diagnostic accuracy for detecting cirrhosis, better at ruling out (high negative predictive value >90%) than ruling in. (LoE 1a, GoR A) (10,0,0)

Clinical decompensation and other clinical endpoints

Liver stiffness measurements obtained with TE are able to predict liver-related events (clinical complications, HCC and liver-related death) as confirmed in a meta-analysis (Singh et al. 2013). As for clinical decompensation, LSMs ≥ 21 kPa were as accurate as HVPG ≥ 10 mm Hg in one study (Robic et al. 2011). LSM by 2-D SWE also predicted clinical decompensation in one study (Grgurevic et al. 2015). For p-SWE, data on this aspect are still lacking.

Spleen stiffness measurements predicted clinical decompensation in one study using TE (Colecchia et al. 2014) and one study using 2-D SWE (Grgurevic et al. 2015). In one study using p-SWE, SSM predicted variceal bleeding (Takuma et al. 2016a).

Changes in LSMs do not correlate with changes in HVPG in patients undergoing therapy with non-selective beta blockers (Reiberger et al. 2012). Yearly LSM to follow up patients with portal hypertension has been suggested (de Franchis and Baveno 2015) but has not been validated yet.

RECOMMENDATION 10: Liver stiffness measurements of TE >20 kPa can be used to identify patients likely bearing clinically significant portal

hypertension (HVPG ≥ 10 mm Hg). (LoE 2b, GoR B) (10,0,0)

RECOMMENDATION 11: Liver stiffness measurement using TE <20–25 kPa combined with platelet count >110–150 $\times 10^6$ /mL is useful in ruling out varices needing treatment. (LoE 2b, GoR B) (10,0,0)

RECOMMENDATION 12: Liver stiffness measurement holds prognostic value in compensated cirrhosis, and the higher the value, the higher is the risk of clinical complications. (LoE 2b, GoR B) (10,0,0)

PEDIATRICS

Preliminary data on SWE techniques including TE, p-SWE and 2-D SWE have been published for the evaluation and follow-up of liver fibrosis in children (Behairy Bel et al. 2016; Belei et al. 2016; Chen et al. 2016a, 2016b; Desai et al. 2016; Ferraioli et al. 2017; Franchi-Abella et al. 2016; Garcovich et al. 2017; Gersak et al. 2016; Ghaffar et al. 2016; Hanquinet et al. 2016; Hattapoglu et al. 2016; Jung et al. 2017; Kamble et al. 2017; Lodwick et al. 2017; Mann et al. 2016; Ozkan et al. 2017; Phelps et al. 2017; Raizner et al. 2017; Tokuhara et al. 2016; Trout et al. 2016; Yoon et al. 2017). Normal values in liver elasticity measured by SE in healthy infants and children were reported (Selmi et al. 2014). In comparison to adult patients, different factors are encountered in children. The age, size and specific anatomy of the patients result in different probe diameters and eventually different examination techniques, including sedation, resulting in different cutoff values. This means that the cooperation of children (including breath-holding) and cooperation of parents have to be taken into account. There is a variety of specific pediatric etiologies of diseases, with different influencing factors as well. In many diseases, the cutoff values are not as precisely known as they should be; therefore, individual follow-up examination plays a major role.

Examination technique and normal values

The Fibroscan S probe (tip diameter of 5 mm compared with 7 mm for the M probe) has been adapted to the needs of children. TE is technically feasible and reliable in children of all age groups, but less successful in children <6 y old. Successful LSMs are even rarer in children <24 mo. The current recommendations from the manufacturer suggest using the S1 probe for thorax diameter <45 cm, S2 for 45–75 cm and M probe for thorax diameter >75 cm. The median and upper limit of normal values increase significantly with age (Engelmann et al. 2012; Lewindon et al. 2016; Tokuhara et al. 2016). The values were 4.4, 4.7 and 5.1 kPa in children 0–5, 6–11 and 12–18 y of age ($p = 0.001$), respectively, while the IQR decreased with age (0.8 0.7, and 0.6 kPa)

(Engelmann *et al.* 2012). In some studies, females exhibited lower median LSMs than males (4.7 vs. 5.6 kPa, $p < 0.005$) (Engelmann *et al.* 2012), but no differences in other studies (Goldschmidt *et al.* 2013; Lewindon *et al.* 2016).

Studies with a smaller number of patients, but with results similar to those obtained with TE data, have been obtained using p-SWE (Bailey *et al.* 2017; Trout *et al.* 2016). In 132 children, the mean value of p-SWE measurements was 1.16 m/s (standard deviation: ± 0.14 m/s) (Eiler *et al.* 2012). Point SWE was feasible in children of any age (Hanquinet *et al.* 2013; Matos *et al.* 2014).

It has been found that three acquisitions of a 2-D SWE technique can be enough for assessing SWSs in children >6 y, regardless of breathing status or hepatic pathology. More acquisitions are recommended for children <5 y, during free breathing (Jung *et al.* 2017; Shin *et al.* 2016).

Published evidence obtained with SE in children is scarce and contradictory (Schenk *et al.* 2014a, 2014b; Selmi *et al.* 2014).

Staging of fibrosis

The correlation of LSM with fibrosis stages has been examined in chronic liver diseases of different etiologies, with promising results (Behairy Bel *et al.* 2016). It must be taken into account that each liver disease may present different cutoff values when interpreting LSM for assessing fibrosis and may also depend on the severity of inflammation. General anesthesia and food intake also significantly increase liver stiffness in healthy children (de Ledinghen *et al.* 2007; Lee *et al.* 2013; Raizner *et al.* 2017). No general conclusions have been drawn so far to allow staging of fibrosis.

Point SWE and 2-D SWE techniques may have advantages in differentiating different stages of fibrosis (Fontanilla *et al.* 2014; Marginean and Marginean 2012; Ozkan *et al.* 2017; Pinto *et al.* 2014; Tomita *et al.* 2013). Liver diseases associated with cystic fibrosis have been examined using p-SWE (Canas *et al.* 2015). With TE as a reference method, the sensitivity of p-SWE for detecting fibrosis F1 was 71.4%, for F2 77.8%, for F3 62.5% and for F4 71.4%. The sensitivity of 2-D SWE for detecting F1 was 92.8%, for F2 83.3%, for F3 87.5% and for F4 85.7%. Significant correlations were found between TE and 2-D SWE (κ correlation factor = 0.843, $p = 0.001$) (Belei *et al.* 2016).

Follow-up examinations

Pediatric diseases are rare; therefore, large studies presenting reliable data in a large cohort of patients are lacking. Follow-up examinations are recommended for pediatric patients with liver diseases to screen for

complications including liver cirrhosis, portal hypertension and malignant transformation (Yoon *et al.* 2017). In patients with biliary atresia, the time for LSMs after the Kasai procedure for liver transplantation is important (Hanquinet *et al.* 2015, 2016) and promising (Chen *et al.* 2016b; Chongsrisawat *et al.* 2011). Follow-up examinations are generally necessary after liver transplantation (Tomita *et al.* 2013).

The combination of TE with pediatric NAFLD fibrosis index has been examined in children with NAFLD to assess the grade of fibrosis (Alkhoury *et al.* 2013). No recommendation can be given so far. CAP (Sasso *et al.* 2010) allows estimation of liver steatosis in pediatric (obese) patients (Desai *et al.* 2016). No recommendation can be given so far.

RECOMMENDATION 13: There is insufficient evidence to make a recommendation on the use of SWE for liver stiffness assessment in pediatric patients. (LoE 5, GoR D)(10,0,0)

FOCAL LIVER LESIONS

Diagnosis of focal liver lesions (FLLs) is needed to identify patients with malignant liver disease, to determine the correct management and to differentiate these patients from those with benign and insignificant pathology. For many years, contrast-enhanced computed tomography and MR scans, and more recently contrast-enhanced ultrasound (CEUS), have shown their value and ability to provide correct diagnoses without the requirement for surgery or biopsy. Currently, the use of elastography for characterization of FLLs remains investigational. It is hoped that elastography may supplement imaging to give more specific diagnoses in selected patients.

Although several reports document that malignant lesions are more likely stiffer than benign lesions, there is significant overlap. Both benign and malignant lesions can be soft or stiff compared with normal liver. In addition, the stiffness of the liver varies significantly with fibrosis. So, in any given patient elastography is not able to characterize liver lesions with significant accuracy for clinical use (Omichi *et al.* 2015; Yu and Wilson 2011). At present, sonoelastography is not recommended for characterization of FLLs (Barr *et al.* 2016b). However, there are a few situations in which FLL stiffness may be of benefit, for example, focal nodular hyperplasia versus hepatic adenoma and in HCC cases (see Supplement 3, online only).

RECOMMENDATION 14: There is insufficient evidence to make a recommendation on the use of SWE for differentiation between benign and malignant lesions and characterization of focal liver lesions. (LoE 5, GoR D) (10,0,0)

ASSESSMENT AND GRADING OF HEPATIC STEATOSIS

Non-alcoholic fatty liver disease is becoming the leading cause of chronic liver disease worldwide. The term comprises a range of conditions, from simple steatosis to NASH. This latter may evolve into cirrhosis and its complications.

Even though liver biopsy is considered the gold standard for steatosis grading, the procedure cannot be used to screen a large population and is unsuitable for monitoring changes that may occur over short periods.

The CAP has been proposed for non-invasive grading liver steatosis (Sasso et al. 2010).

Failure

In a prospective study of 5323 examinations performed in patients with chronic liver diseases with the M probe, the CAP failure rate (defined as no results) was 7.7% (de Ledinghen et al. 2014). The factors independently associated with CAP failure were female, overweight or obesity and metabolic syndrome, consistent with those already reported for liver stiffness (Castera et al. 2010). In another recent study based on 1696 examinations, in 992 NAFLD patients, in whom both M and XL probes were used depending on the skin-to-liver capsule distance, the failure rate was lower: 3.2% (Vuppalanchi et al. 2018).

Reproducibility

Reproducibility has been assessed in two independent studies using the M probe (Ferraioli et al. 2014b; Recio et al. 2013). The concordance between observers was excellent, 0.82 (95% CI: 0.78–0.85) (Pineda et al. 2009) and 0.84 (95% CI: 0.77–0.88) (Recio et al. 2013), respectively. However, the agreement between raters decreased for body mass index (BMI) >30 kg/m² (0.65) and for CAP values <240 dB/m (0.44) (Ferraioli et al. 2014b).

A recent study of 838 NAFLD patients (BMI: 33.6 ± 6.5 kg/m²), in whom both the M and XL probes were used, found that the intra-observer and inter-observer correlations were high overall: $r=0.82$ and $r=0.70$, respectively. However, the correlation decreased with the XL probe (M probe vs. the XL probe: intra-observer correlation: $r=0.85$ vs. 0.75 , $p=0.0003$; inter-observer correlation $r=0.64$ vs. 0.68 , $p=0.71$) (Vuppalanchi et al. 2018).

Quality criteria

In the absence of specific quality criteria provided by the manufacturer, investigators have used those used for LSM. Recently, an international multicenter study, including 754 consecutive patients, in whom CAP was measured with the M probe before liver biopsy, reported

that the accuracy of CAP declined when its IQR was >40 dB/m (with an AUROC for fatty liver of 0.77 vs. 0.90 in patients with IQR <40 dB/m, $p=0.004$) (Wong et al. 2017). The authors suggested that an IQR <40 dB/m could be used as a quality criterion. These findings require further external validation before any recommendation can be made.

Accuracy and cutoff values (comparison with histologic steatosis grade)

Several studies have found that CAP values correlate with the histologic grades of steatosis; however, there is a large overlap between adjacent grades. Cutoff values varied between studies; however, the cutoff value associated with significant steatosis (>33% of hepatocytes) was almost always around 250 dB (Castera 2015). A summary table on the performance of CAP for grading steatosis has recently been published (Castera 2015). CAP values are not influenced by liver fibrosis and cirrhosis (de Ledinghen et al. 2012a; Ferraioli et al. 2014a; Kumar et al. 2013; Myers et al. 2012; Sasso et al. 2012).

In a recent individual data meta-analysis based on 19 studies and 2735 patients (hepatitis B 37%, hepatitis C 36%, NAFLD/NASH 20%, other etiologies 7%), 1391 patients had S0 grade, 754 S1 grade, 427 S2 grade and 163 S3 grade (Karlas et al. 2017). Optimal cutoff values and 95% confidence intervals were 248 (237–261) dB/m for S >0, 268 (257–284) dB/m for S >1 and 280 (268–294) dB/m for S >2. AUROCs were 0.82 (0.81–0.84), 0.86 (0.85–0.88) and 0.88 (0.86–0.91), respectively. Sensitivities were 0.69 (0.60–0.75), 0.77 (0.69–0.84) and 0.88 (0.76–0.96), and specificities were 0.82 (0.76–0.90), 0.81 (0.75–0.88) and 0.78 (0.72–0.82), respectively. CAP values were influenced by several covariates, including NAFLD, diabetes and BMI. The authors proposed adapting the proposed cutoff values by adding 10 (95% CI: 4.5–17) dB/m for NAFLD/NASH patients, 10 (95% CI: 3.5–16) dB/m for diabetic patients and 4.4 (95% CI: 3.8–5.0) dB/m per BMI unit.

A study has indicated that histologic steatosis grade 3 and high CAP values independently affect the diagnostic performance of CAP (Jung et al. 2014).

A recent study reported that in patients with NAFLD, CAP values >300 dB/m may lead to overestimation of liver fibrosis assessed by TE, especially in patients with lower stages of fibrosis (Petta et al. 2017). However, the influence of steatosis on LSM in NAFLD remains debated.

M and XL probes

Two studies compared the performance of CAP with M and XL probes using liver biopsy as the

reference standard with conflicting results. In a study in 236 Western patients with chronic liver disease (mean BMI: 24.4 ± 6.3), the performances and cutoff values were similar (de Ledinghen *et al.* 2017), whereas in another study conducted in 57 NAFLD Chinese patients (mean BMI: 30.2 ± 5.0), performance was similar, but cutoff values were higher with the XL probe (Chan *et al.* 2017). Thus, further studies are necessary before any firm conclusions can be drawn.

Comparison with the US signs of liver steatosis

Few studies, all carried out with small samples, are available. Only two studies have performed a head-to-head comparison with liver biopsy as reference: one in patients with chronic liver disease (de Ledinghen *et al.* 2012a) and the other in patients with chronic hepatitis B (Xu *et al.* 2017a). Both studies indicated that the performance of CAP for detecting and grading liver steatosis was higher than that of US; however, the rate of overestimation was significantly higher for CAP than for US (30.5% vs. 12.4%, $p < 0.05$) (Xu *et al.* 2017a).

A study that has assessed the diagnostic accuracy of CAP in comparison with US for detection and quantification of hepatic steatosis in the general population reported that CAP significantly correlated with steatosis; the AUROCs were 0.94 (95% CI: 0.91–0.97) for significant steatosis and 0.95 (95% CI: 0.90–0.99) for severe steatosis (Carvalhana *et al.* 2014). It has been reported that in patients with advanced liver fibrosis, CAP performs better than US in assessing liver steatosis (Ferraioli *et al.* 2016b). The US findings of liver fibrosis and steatosis could be similar, and this may decrease the diagnostic accuracy of US. No data in NAFLD patients are available.

By use of the imperfect gold standard methodology in a series of overweight or obese children, it has been reported that for the evaluation of liver steatosis in children, CAP performs better than US, and a cutoff value for CAP of 249 dB/m rules in liver steatosis with 0.98 (0.97–0.98) specificity (Ferraioli *et al.* 2017).

Comparison with magnetic resonance (proton density fat fraction)

Studies that have assessed the diagnostic accuracy of CAP compared with proton density fat fraction (PDFF) magnetic resonance (MR) spectroscopy, using liver biopsy as reference, have reported that CAP is outperformed by MRI-PDFF for steatosis grading. In a study on 142 patients with NAFLD, CAP identified hepatic steatosis grade ≥ 2 with an AUROC of 0.73 (95% CI: 0.64–0.81), whereas PDFF yielded an AUROC of 0.90 (95% CI: 0.82–0.97, $p < 0.001$) (Imajo *et al.* 2016). In another study on 55 patients suspected of having NAFLD,

both PDFF and CAP detected histologically proven steatosis ($\geq S1$), but PDFF had better diagnostic accuracy than CAP in terms of AUROCs (0.99 vs. 0.77, respectively; $p = 0.0334$) (Runge *et al.* 2017). Likewise, another study in 104 consecutive patients reported that MRI-PDFF is more accurate than CAP in detecting all grades of steatosis in patients with NAFLD (Park *et al.* 2017). MRI-PDFF identified steatosis of grade 2 or 3 with AUROC values of 0.90 (95% CI: 0.82–0.97) and 0.92 (95% CI: 0.84–0.99); CAP identified steatosis of grade 2 or 3 with AUROC values of 0.70 (95% CI: 0.58–0.82) and 0.73 (95% CI: 0.58–0.89).

A study that assessed the accuracy of CAP using magnetic resonance spectroscopy as the reference standard in HIV-infected patients found that the results obtained with the two techniques correlated well; however, patients with higher body composition parameters were more likely to be misclassified as having hepatic steatosis by CAP (Price *et al.* 2017).

Follow-up

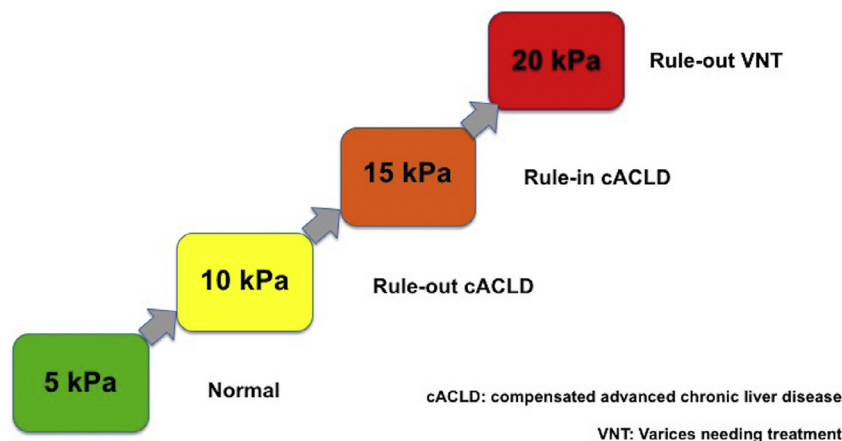
Longitudinal studies are awaited. Recently, a study that followed up 4282 patients who had both a reliable LSM and ≥ 10 successful CAP measurements reported that neither the presence nor the severity of hepatic steatosis predicted liver-related events, cancer or cardiovascular events in the short term, while LSM and etiology independently predicted liver-related events (Liu *et al.* 2017). Subgroup analyses of viral hepatitis (hepatitis B: 37.0%, hepatitis C: 2.9%) and NAFLD patients (40.7% of the entire cohort) revealed similar results.

Summary

The controlled attenuation parameter is a promising point-of-care technique for rapid and standardized steatosis quantification, but needs to be better validated in patients with NAFLD with the XL probe. CAP quality criteria are not well defined. There are no consensual cutoff values, and the influence of BMI and diabetes should be further explored. More data are needed with the XL probe in NAFLD patients, who are the target population, and for the comparison with US, taking liver biopsy as the reference standard. Longitudinal studies are awaited. CAP is outperformed by MRI-PDFF.

Current technological advances of imaging ultrasound systems are directed at grading steatosis. However, no studies are available yet.

RECOMMENDATION 15: CAP is a point-of-care, standardized and reproducible technique, promising for the detection of liver steatosis. However, for quantifying steatosis there is a large overlap between adjacent grades, there are no consensual



De Franchis R & Baveno VI faculty. *J Hepatol* 2015; 63: 237-64.

Fig. 1. Rule of 5. cACLD = compensated advanced chronic liver disease; VNT = varices needing treatment. Reprinted, with permission, from de Franchis and Baveno (2015).

cutoffs and quality criteria are not well defined.
(LoE 3, GoR C) (10,0,0)

Practical advice for interpretation of liver stiffness values

There is significant overlap of stiffness values for the varying degrees of liver fibrosis. All techniques have high accuracy for normal patients and most patients with cirrhosis. However, degrees of liver stiffness between these two extremes overlap substantially. One approach is to use a cutoff value system as recommended by the SRU, with a low cutoff below which there is a high probability of being normal or having minimal fibrosis and a high cutoff value where there is a high probability of significant fibrosis or cirrhosis (Barr et al. 2016a). Some patients with biopsy-proven cirrhosis have had relatively low stiffness values in many studies. Another clinical approach to interpreting liver stiffness values would be in keeping with that recommended for TE by the Baveno VI Conference (de Franchis and Baveno 2015). The so-called “rule of 5” (Young’s modulus 5, 10, 15 and 20 kPa) could be recommended (Fig. 1): LS <5 kPa has a high probability of being normal; LS <10 kPa, in the absence of other known clinical signs, rules out compensated advanced chronic liver disease. Values between 10 and 15 kPa are suggestive of compensated advanced chronic liver disease, but need further tests for confirmation. Values >15 kPa are highly suggestive of compensated advanced chronic liver disease. Values ≥ 20 –25 kPa can rule in CSPH.

Recommendation 16: Interpretation of liver stiffness measurements needs to be taken in context with the other clinical and laboratory data. (LoE 1b, GoR A) (10,0,0)

Table 3. Items to be delineated when performing liver elastography studies

Machine(s) utilized, procedure (transient elastography, point shear wave elastography, 2-D shear wave elastography), probe, quality criteria
Population (body mass index, alcoholism, comorbidities, transaminase levels, platelet count)
Context of use (specialty clinic, general practice, academic institution, etc.)
Confounding factors (fasting, etc.)
Operators (number, degree of training, experience)
Reference standard for validation study and interventional studies
If liver biopsy is used for gold standard; size of specimens, central reading, interval between liver biopsy and elastographic procedure

Minimal requirements for future studies

When studies evaluating liver elastography are performed, it is recommended that the items in Table 3 be included in the methodology, to allow for better comparison between studies and techniques. The Statement for Reporting Studies of Diagnostic Accuracy (STARD checklist) should be used before starting studies of diagnostic accuracy.

ACKNOWLEDGMENTS

The authors thank the following companies for funding a consensus meeting of the authors held in Chicago in December 2017: Echosens, Esaote, GE Healthcare, Hitachi Ltd., Philips Healthcare, Siemens Healthineer, Supersonic Imagine and Canon Medical Systems. Representatives of these companies were in attendance at this meeting to assist with the technique information, but did not take part in developing this article.

The authors gratefully acknowledge Lynne Rudd from the WFUMB office for efficient management.

CONFLICT OF INTEREST DISCLOSURE

G.F. has served as speaker for Philips Healthcare, Hitachi Ltd., Canon Medical Systems and Mindray Medical Systems.

V.W-S.W. has served as an advisory board member for AbbVie, Allergan, Center for Outcomes Research in Liver Diseases, Gilead Sciences, Janssen, Perspectum Diagnostics and Pfizer; he has also received lecture fees from Bristol-Myers Squibb, Echosens, Gilead Sciences and Merck.

L.C. has served as an advisory member for Gilead Sciences, Merck and Sirtex; he has also received lecture fees from Abbvie, Echosens, Gilead, Intercept and Sirtex.

A.B. has received a research grant from Gilead Sciences and received a lecture fee from Echosens.

I.S. has served as speaker and an advisory board member for AbbVie, Gilead Sciences, Bristol-Myers Squibb, MSD, Philips Healthcare, Siemens Healthcare and General Electric Ultrasound.

C.F.D. is on the speakers' bureaus of Bracco Diagnostics, Hitachi Aloka Medical Systems, Supersonics Imagine, Siemens Healthineers, Mindray, GE, AbbVie and Novartis; he is also on the advisory panels of Hitachi Medical Systems, Siemens Healthineers and Mindray.

B.I.C. has nothing to declare.

S.R.W. has received equipment grants from Siemens, Philips and Samsung and a research grant from Lantheus Medical.

M.K. has received lecture fees from Bayer, Eisai, MSD and Ajinomoto and research grants from Chugai, Otsuka, Takeda, Taiho, Sumitomo Dainippon, Daiichi Sankyo, MSD, Eisai, Bayer, Abbvie, Medico's Hirata, Astellas Pharma and Bristol-Myers Squibb; he is also on the advisory panels of Kowa, MSD, BMS, Bayer, Chugai, Taiho, Eisai and Ono Pharmaceutical.

R.G.B. has received research grants from Siemens Ultrasound, Philips Ultrasound, SuperSonic Imagine, GE Ultrasound, B and K Ultrasound, Bracco Diagnostics; he is on the speakers' bureaus of Philips Ultrasound, Bracco Diagnostics and Lantheus Medical; is on the advisory panels of Bracco Diagnostics and Lantheus Medical; and has received royalties from Thieme Publishers.

SUPPLEMENTARY MATERIALS

Supplementary material associated with this article can be found, in the online version, at [doi:10.1016/j.ultrasmedbio.2018.07.008](https://doi.org/10.1016/j.ultrasmedbio.2018.07.008).

REFERENCES

- Abdalla AF, Zalata KR, Ismail AF, Shiha G, Attiya M, Abo-Alyazeeed A. Regression of fibrosis in paediatric autoimmune hepatitis: Morphometric assessment of fibrosis versus semiquantitative methods. *Fibrogenesis Tissue Repair* 2009;2:2.
- Abraldes JG, Bureau C, Stefanescu H, Augustin S, Ney M, Blasco H, Procopet B, Bosch J, Genesca J, Berzigotti A. for the Anticipate investigators. Noninvasive tools and risk of clinically significant portal hypertension and varices in compensated cirrhosis: The "Anticipate" study. *Hepatology* 2016;64:2173–2183.
- Alkhoury N, Sedki E, Alisi A, Lopez R, Pinzani M, Feldstein AE, Nobili V. Combined paediatric NAFLD fibrosis index and transient elastography to predict clinically significant fibrosis in children with fatty liver disease. *Liver Int* 2013;33:79–85.
- Anastasiou J, Alisa A, Virtue S, Portmann B, Murray-Lyon I, Williams R. Noninvasive markers of fibrosis and inflammation in clinical practice: Prospective comparison with liver biopsy. *Eur J Gastroenterol Hepatol* 2010;22:474–480.
- Anastasiou OE, Buchter M, H AB, Korth J, Canbay A, Gerken G, Kahraman A. Performance and utility of transient elastography and non-invasive markers of liver fibrosis in patients with autoimmune hepatitis: A single centre experience. *Hepat Mo* 2016;16:e40737.
- Attia D, Schoenemeier B, Rodt T, Negm AA, Lenzen H, Lankisch TO, Manns M, Gebel M, Potthoff A. Evaluation of liver and spleen stiffness with acoustic radiation force impulse quantification elastography for diagnosing clinically significant portal hypertension. *Ultraschall Med* 2015;36:603–610.
- Augustin S, Pons M, Maurice JB, Bureau C, Stefanescu H, Ney M, Blasco H, Procopet B, Tsochatzis E, Westbrook RH, Bosch J, Berzigotti A, Abraldes JG, Genesca J. Expanding the Baveno VI criteria for the screening of varices in patients with compensated advanced chronic liver disease. *Hepatology* 2017;66:1980–1988.
- Bailey SS, Youssfi M, Patel M, Hu HH, Shaibi GQ, Towbin RB. Shear-wave ultrasonography of the liver in normal-weight and obese children. *Acta Radiol* 2017;58:1511–1518.
- Bardou-Jacquet E, Legros L, Soro D, Latournerie M, Guillygomarc'h A, Le Lan C, Brissot P, Guyader D, Moirand R. Effect of alcohol consumption on liver stiffness measured by transient elastography. *World J Gastroenterol* 2013;19:516–522.
- Barr RG, Ferraioli G, Levine D. Response. *Radiology* 2016;278:303–304.
- Barr RG, Ferraioli G, Palmeri ML, Goodman ZD, Garcia-Tsao G, Rubin J, Garra B, Myers RP, Wilson SR, Rubens D, Levine D. Elastography assessment of liver fibrosis: Society of Radiologists in Ultrasound Consensus Conference Statement. *Ultrasound Q* 2016b;32:94–107.
- Behairy Bel S, Sira MM, Zalata KR, Salama el SE, Abd-Allah MA. Transient elastography compared to liver biopsy and morphometry for predicting fibrosis in pediatric chronic liver disease: Does etiology matter? *World J Gastroenterol* 2016;22:4238–4249.
- Belei O, Sporea I, Gradinaru-Tascau O, Olariu L, Popescu A, Simeanea I, Marginean O. Comparison of three ultrasound based elastographic techniques in children and adolescents with chronic diffuse liver diseases. *Med Ultrasonogr* 2016;18:145–150.
- Bellentani S, Saccoccio G, Costa G, Tiribelli C, Manenti F, Sodde M, Saveria Croce L, Sasso F, Pozzato G, Cristianini G, Brandi G. Drinking habits as cofactors of risk for alcohol induced liver damage. The Dionysos Study Group. *Gut* 1997;41:845–850.
- Berzigotti A. Non-invasive evaluation of portal hypertension using ultrasound elastography. *J Hepatol* 2017;67:399–411.
- Berzigotti A, Seijo S, Arena U, Abraldes JG, Vizzutti F, Garcia-Pagan JC, Pinzani M, Bosch J. Elastography, spleen size, and platelet count identify portal hypertension in patients with compensated cirrhosis. *Gastroenterology* 2013;144:102–111.e101.
- Berzigotti A, Ferraioli G, Bota S, Gilja OH, Dietrich CF. Novel ultrasound-based methods to assess liver disease: The game has just begun. *Dig Liver Dis* 2018;50:107–112.
- Bota S, Sporea I, Peck-Radosavljevic M, Sirlir R, Tanaka H, Iijima H, Saito H, Ebinuma H, Lupsor M, Badea R, Fierbinteanu-Braticевич C, Petrisor A, Friedrich-Rust M, Sarrazin C, Takahashi H, Ono N, Piscaglia F, Marinelli S, D'Onofrio M, Gallotti A, Salzl P, Popescu A, Danila M. The influence of aminotransferase levels on liver stiffness assessed by acoustic radiation force impulse elastography: A retrospective multicentre study. *Dig Liver Dis* 2013;45:762–768.
- Boursier J, Konate A, Gorea G, Reaud S, Quemener E, Oberti F, Hubert-Fouchard I, Dib N, Cales P. Reproducibility of liver stiffness measurement by ultrasonographic elastometry. *Clin Gastroenterol Hepatol* 2008a;6:1263–1269.
- Boursier J, Konate A, Guilluy M, Gorea G, Sawadogo A, Quemener E, Oberti F, Reaud S, Hubert-Fouchard I, Dib N, Cales P. Learning curve and interobserver reproducibility evaluation of liver stiffness measurement by transient elastography. *Eur J Gastroenterol Hepatol* 2008b;20:693–701.
- Boursier J, Vergniol J, Sawadogo A, Dakka T, Michalak S, Gallois Y, Le Tallec V, Oberti F, Fouchard-Hubert I, Dib N, Rousselet MC, Konate A, Amrani N, de Ledinghen V, Cales P. The combination of a blood test and Fibroscan improves the non-invasive diagnosis of liver fibrosis. *Liver Int* 2009;29:1507–1515.
- Canas T, Macia A, Munoz-Codoceo RA, Fontanilla T, Gonzalez-Rios P, Miralles M, Gomez-Mardones G. Hepatic and splenic acoustic radiation force impulse shear wave velocity elastography in children with liver disease associated with cystic fibrosis. *BioMed Res Int* 2015;2015 517369.
- Carvalhoana S, Leitao J, Alves AC, Bourbon M, Cortez-Pinto H. How good is controlled attenuation parameter and fatty liver index for assessing liver steatosis in general population: correlation with ultrasound. *Liver Int* 2014;34:e111–e117.
- Cassinotto C, Lapuyade B, Ait-Ali A, Vergniol J, Gaye D, Foucher J, Bailacq-Auder C, Chermak F, Le Bail B, de Ledinghen V. Liver fibrosis: Noninvasive assessment with acoustic radiation force

- impulse elastography—Comparison with FibroScan M and XL probes and FibroTest in patients with chronic liver disease. *Radiology* 2013;269:283–292.
- Cassinotto C, Lapuyade B, Mouries A, Hiriart JB, Vergniol J, Gaye D, Castain C, Le Bail B, Chermak F, Foucher J, Laurent F, Montaudon M, De Ledinghen V. Non-invasive assessment of liver fibrosis with impulse elastography: Comparison of Supersonic Shear Imaging with ARFI and FibroScan®. *J Hepatol* 2014;61:550–557.
- Cassinotto C, Boursier J, de Ledinghen V, Lebigot J, Lapuyade B, Cales P, Hiriart JB, Michalak S, Bail BL, Cartier V, Mouries A, Oberti F, Fouchard-Hubert I, Vergniol J, Aube C. Liver stiffness in nonalcoholic fatty liver disease: A comparison of supersonic shear imaging, FibroScan, and ARFI with liver biopsy. *Hepatology* 2016;63:1817–1827.
- Castera L, Foucher J, Bernard PH, Carvalho F, Allaix D, Merrouche W, Couzigou P, de Ledinghen V. Pitfalls of liver stiffness measurement: A 5-year prospective study of 13,369 examinations. *Hepatology* 2010;51:828–835.
- Castera L. Noninvasive evaluation of nonalcoholic fatty liver disease. *Semin Liver Dis* 2015;35:291–303.
- Chan HL, Wong GL, Choi PC, Chan AW, Chim AM, Yiu KK, Chan FK, Sung JJ, Wong VW. Alanine aminotransferase-based algorithms of liver stiffness measurement by transient elastography (Fibroscan) for liver fibrosis in chronic hepatitis B. *J Viral Hepat* 2009;16:36–44.
- Chan J, Gogela N, Zheng H, Lammert S, Ajayi T, Fricker Z, Kim AY, Robbins GK, Chung RT. Direct-acting antiviral therapy for chronic HCV infection results in liver stiffness regression over 12 months post-treatment. *Dig Dis Sci* 2018;63:486–492.
- Chan WK, Nik Mustapha NR, Wong GL, Wong VW, Mahadeva S. Controlled attenuation parameter using the FibroScan®XL probe for quantification of hepatic steatosis for non-alcoholic fatty liver disease in an Asian population. *United Eur Gastroenterol J* 2017;5:76–85.
- Chang S, Kim MJ, Kim J, Lee MJ. Variability of shear wave velocity using different frequencies in acoustic radiation force impulse (ARFI) elastography: A phantom and normal liver study. *Ultraschall Med* 2013;34:260–265.
- Chen B, Schreiber RA, Human DG, Potts JE, Guttman OR. Assessment of liver stiffness in pediatric Fontan patients using transient elastography. *Can J Gastroenterol Hepatol* 2016a;2016: 7125193.
- Chen S, Liao B, Zhong Z, Zheng Y, Liu B, Shan Q, Xie X, Zhou L. Supersonic shearwave elastography in the assessment of liver fibrosis for postoperative patients with biliary atresia. *Sci Rep* 2016b;6:31057.
- Choi SY, Jeong WK, Kim Y, Kim J, Kim TY, Sohn JH. Shear-wave elastography: A noninvasive tool for monitoring changing hepatic venous pressure gradients in patients with cirrhosis. *Radiology* 2014;273:917–926.
- Chongsrisawat V, Vejapipat P, Siripon N, Poovorawan Y. Transient elastography for predicting esophageal/gastric varices in children with biliary atresia. *BMC Gastroenterol* 2011;11:41.
- Colecchia A, Colli A, Casazza G, Mandolesi D, Schiumerini R, Reggiani LB, Marasco G, Taddia M, Lisotti A, Mazzella G, Di Biase AR, Golfieri R, Pinzani M, Festi D. Spleen stiffness measurement can predict clinical complications in compensated HCV-related cirrhosis: a prospective study. *J Hepatol* 2014;60:1158–1164.
- Corpechot C, Carrat F, Poujol-Robert A, Gaouar F, Wendum D, Chazouilleres O, Poupon R. Noninvasive elastography-based assessment of liver fibrosis progression and prognosis in primary biliary cirrhosis. *Hepatology* 2012;56:198–208.
- Corpechot C, Gaouar F, El Naggar A, Kemgang A, Wendum D, Poupon R, Carrat F, Chazouilleres O. Baseline values and changes in liver stiffness measured by transient elastography are associated with severity of fibrosis and outcomes of patients with primary sclerosing cholangitis. *Gastroenterology* 2014;146:970–979; quiz e915–e976.
- Cui XW, Pirri C, Ignee A, De Molo C, Hirche TO, Schreiber-Dietrich DG, Dietrich CF. Measurement of shear wave velocity using acoustic radiation force impulse imaging is not hampered by previous use of ultrasound contrast agents. *Z Gastroenterol* 2014;52:649–653.
- de Franchis R, Baveno VIF. Expanding consensus in portal hypertension: Report of the Baveno VI Consensus Workshop: Stratifying risk and individualizing care for portal hypertension. *J Hepatol* 2015;63:743–752.
- de Ledinghen V, Le Bail B, Rebouissoux L, Fournier C, Foucher J, Miette V, Castera L, Sandrin L, Merrouche W, Lavrand F, Lamirreau T. Liver stiffness measurement in children using FibroScan: Feasibility study and comparison with Fibrotest, aspartate transaminase to platelets ratio index, and liver biopsy. *J Pediatr Gastroenterol Nutr* 2007;45:443–450.
- de Ledinghen V, Vergniol J, Foucher J, Merrouche W, le Bail B. Non-invasive diagnosis of liver steatosis using controlled attenuation parameter (CAP) and transient elastography. *Liver Int* 2012a;32:911–918.
- de Ledinghen V, Wong VW, Vergniol J, Wong GL, Foucher J, Chu SH, Le Bail B, Choi PC, Chermak F, Yiu KK, Merrouche W, Chan HL. Diagnosis of liver fibrosis and cirrhosis using liver stiffness measurement: Comparison between M and XL probe of FibroScan®. *J Hepatol* 2012b;56:833–839.
- de Ledinghen V, Vergniol J, Capdepon M, Chermak F, Hiriart JB, Cassinotto C, Merrouche W, Foucher J, Brigitte le B. Controlled attenuation parameter (CAP) for the diagnosis of steatosis: A prospective study of 5323 examinations. *J Hepatol* 2014;60: 1026–1031.
- de Ledinghen V, Hiriart JB, Vergniol J, Merrouche W, Bedossa P, Paradis V. Controlled attenuation parameter (CAP) with the XL probe of the Fibroscan®: A comparative study with the M probe and liver biopsy. *Dig Dis Sci* 2017;62:2569–2577.
- Desai NK, Harney S, Raza R, Al-Ibraheemi A, Shillingford N, Mitchell PD, Jonas MM. Comparison of controlled attenuation parameter and liver biopsy to assess hepatic steatosis in pediatric patients. *J Pediatr* 2016;173:160–164.e161.
- Di Marco V, Calvaruso V, Ferraro D, Bavetta MG, Cabibbo G, Conte E, Camma C, Grimaudo S, Pipitone RM, Simone F, Peralta S, Arini A, Craxi A. Effects of eradicating hepatitis C virus infection in patients with cirrhosis differ with stage of portal hypertension. *Gastroenterology* 2016;151:130–139.e132.
- Dietrich CF, Bamber J, Berzigotti A, Bota S, Cantisani V, Castera L, Cosgrove D, Ferraioli G, Friedrich-Rust M, Gilja OH, Goertz RS, Karlas T, de Knecht R, de Ledinghen V, Piscaglia F, Procopet B, Saftoiu A, Sidhu PS, Sporea I, Thiele M. EFSUMB guidelines and recommendations on the clinical use of liver ultrasound elastography, update 2017 (long version). *Ultraschall Med* 2017a; 38:e16–e47.
- Dietrich CF, Bamber J, Berzigotti A, Bota S, Cantisani V, Castera L, Cosgrove D, Ferraioli G, Friedrich-Rust M, Gilja OH, Goertz RS, Karlas T, de Knecht R, de Ledinghen V, Piscaglia F, Procopet B, Saftoiu A, Sidhu PS, Sporea I, Thiele M. EFSUMB guidelines and recommendations on the clinical use of liver ultrasound elastography, update 2017 (short version). *Ultraschall Med* 2017b;38: 377–394.
- Dolman GE, Nieboer D, Steyerberg EW, Harris S, Ferguson A, Zaitoun AM, Ryder SD, James MW, Aithal GP, Guha IN. The performance of transient elastography compared to clinical acumen and routine tests—What is the incremental diagnostic value? *Liver Int* 2013;33:172–179.
- Dyson J, Jaques B, Chattopadhyay D, Lochan R, Graham J, Das D, Aslam T, Patanwala I, Gaggar S, Cole M, Sumpter K, Stewart S, Rose J, Hudson M, Manas D, Reeves HL. Hepatocellular cancer: The impact of obesity, type 2 diabetes and a multidisciplinary team. *J Hepatol* 2014;60:110–117.
- Efe C, Gungoren MS, Ozaslan E, Akbiyik F, Kav T. Acoustic radiation force impulse (ARFI) for fibrosis staging in patients with autoimmune hepatitis. *Hepato-gastroenterology* 2015;62:670–672.
- Eiler J, Kleinholdermann U, Albers D, Dahms J, Hermann F, Behrens C, Luedemann M, Klingmueller V, Alzen GF. Standard value of ultrasound elastography using acoustic radiation force impulse

- imaging (ARFI) in healthy liver tissue of children and adolescents. *Ultraschall Med* 2012;33:474–479.
- Elkrief L, Rautou PE, Ronot M, Lambert S, Dioguardi Burgio M, Francoz C, Plessier A, Durand F, Valla D, Lebrech D, Vilgrain V, Castera L. Prospective comparison of spleen and liver stiffness by using shear-wave and transient elastography for detection of portal hypertension in cirrhosis. *Radiology* 2015;275:589–598.
- Engelmann G, Gebhardt C, Wenning D, Wuhl E, Hoffmann GF, Selmi B, Grulich-Henn J, Schenk JP, Teufel U. Feasibility study and control values of transient elastography in healthy children. *Eur J Pediatr* 2012;171:353–360.
- European Association for the Study of the Liver (EASL). EASL recommendations on treatment of hepatitis C 2015. *J Hepatol* 2015a;63:199–236.
- European Association for the Study of the Liver (EASL)–Asociacion Latinoamericana para el Estudio del Hgado (ALEH). EASL–ALEH clinical practice guidelines: Non-invasive tests for evaluation of liver disease severity and prognosis. *J Hepatol* 2015b;63:237–264.
- European Association for the Study of the Liver (EASL). EASL 2017 clinical practice guidelines on the management of hepatitis B virus infection. *J Hepatol* 2017;67:370–398.
- Facciorusso A, Del Prete V, Turco A, Buccino RV, Nacchiero MC, Muscatiello N. Long-term liver stiffness assessment in HCV patients undergoing antiviral therapy: Results from a 5-year cohort study. *J Gastroenterol Hepatol* 2018. doi: 10.1111/jgh.14008.
- Fang C, Konstantatou E, Romanos O, Yusuf GT, Quinlan DJ, Sidhu PS. Reproducibility of 2-dimensional shear wave elastography assessment of the liver: A direct comparison with point shear wave elastography in healthy volunteers. *J Ultrasound Med* 2017;36:1563–1569.
- Fang C, Jaffer OS, Yusuf GT, Konstantatou E, Quinlan DJ, Agarwal K, Quaglia A, Sidhu PS. Reducing the number of measurements in liver point shear-wave elastography: Factors that influence the number and reliability of measurements in assessment of liver fibrosis in clinical practice. *Radiology* 2018;287: 172104.
- Ferraioli G, Tinelli C, Zicchetti M, Above E, Poma G, Di Gregorio M, Filice C. Reproducibility of real-time shear wave elastography in the evaluation of liver elasticity. *Eur J Radiol* 2012;81:3102–3106.
- Ferraioli G, Tinelli C, Lissandrin R, Zicchetti M, Dal Bello B, Filice G, Filice C. Controlled attenuation parameter for evaluating liver steatosis in chronic viral hepatitis. *World J Gastroenterol* 2014a;20:6626–6631.
- Ferraioli G, Tinelli C, Lissandrin R, Zicchetti M, Rondanelli M, Perani G, Bernuzzi S, Salvaneschi L, Filice C. Interobserver reproducibility of the controlled attenuation parameter (CAP) for quantifying liver steatosis. *Hepatol Int* 2014b;8:576–581.
- Ferraioli G, Filice C, Castera L, Choi BI, Sporea I, Wilson SR, Cosgrove D, Dietrich CF, Amy D, Bamber JC, Barr R, Chou YH, Ding H, Farrokhi A, Friedrich-Rust M, Hall TJ, Nakashima K, Nightingale KR, Palmeri ML, Schafer F, Shiina T, Suzuki S, Kudo M. WFUMB guidelines and recommendations for clinical use of ultrasound elastography: Part 3. Liver. *Ultrasound Med Biol* 2015;41:1161–1179.
- Ferraioli G, Maiocchi L, Lissandrin R, Tinelli C, De Silvestri A, Filice C, Liver Fibrosis Study G. Accuracy of the ElastPQ Technique for the assessment of liver fibrosis in patients with chronic hepatitis C: A “real life” single center study. *J Gastrointest Liver Dis* 2016a;25:331–335.
- Ferraioli G, Tinelli C, De Silvestri A, Lissandrin R, Above E, Dellafiore C, Poma G, Di Gregorio M, Maiocchi L, Maserati R, Filice C. The clinical value of controlled attenuation parameter for the non-invasive assessment of liver steatosis. *Liver Int* 2016b;36:1860–1866.
- Ferraioli G, Calcaterra V, Lissandrin R, Guazzotti M, Maiocchi L, Tinelli C, De Silvestri A, Regalbutto C, Pelizzo G, Larizza D, Filice C. Noninvasive assessment of liver steatosis in children: The clinical value of controlled attenuation parameter. *BMC Gastroenterol* 2017;17:61.
- Ferraioli G, De Silvestri A, Lissandrin R, Maiocchi L, Tinelli C, Filice C, Barr RG. Evaluation of inter-system variability in liver stiffness measurements. *Ultraschall Med* 2018 March.
- Fierbinteanu Braticевич C, Sporea I, Panaitescu E, Tribus L. Value of acoustic radiation force impulse imaging elastography for non-invasive evaluation of patients with nonalcoholic fatty liver disease. *Ultrasound Med Biol* 2013;39:1942–1950.
- Fitzpatrick E, Quaglia A, Vimalasvaran S, Basso MS, Dhawan A. Transient elastography is a useful noninvasive tool for the evaluation of fibrosis in paediatric chronic liver disease. *J Pediatr Gastroenterol Nutr* 2013;56:72–76.
- Fontanilla T, Canas T, Macia A, Alfageme M, Gutierrez Junquera C, Malalana A, Luz Cilleruelo M, Roman E, Miralles M. Normal values of liver shear wave velocity in healthy children assessed by acoustic radiation force impulse imaging using a convex probe and a linear probe. *Ultrasound Med Biol* 2014;40:470–477.
- Franchi-Abella S, Corno L, Gonzales E, Antoni G, Fabre M, Ducot B, Pariente D, Gennisson JL, Tanter M, Correas JM. Feasibility and diagnostic accuracy of Supersonic shear-wave elastography for the assessment of liver stiffness and liver fibrosis in children: A pilot study of 96 patients. *Radiology* 2016;278:554–562.
- Fraquelli M, Rigamonti C, Casazza G, Conte D, Donato MF, Ronchi G, Colombo M. Reproducibility of transient elastography in the evaluation of liver fibrosis in patients with chronic liver disease. *Gut* 2007;56:968–973.
- Fraquelli M, Baccarin A, Casazza G, Conti CB, Giunta M, Massironi S, Invernizzi F, Donato MF, Maggioni M, Aghemo A, Conte D, Colombo M. Liver stiffness measurement reliability and main determinants of point shear-wave elastography in patients with chronic liver disease. *Aliment Pharmacol Ther* 2016;44:356–365.
- Friedrich-Rust M, Hadji-Hosseini H, Kriener S, Herrmann E, Sircar I, Kau A, Zeuzem S, Bojunga J. Transient elastography with a new probe for obese patients for non-invasive staging of non-alcoholic steatohepatitis. *Eur Radiol* 2010;20:2390–2396.
- Friedrich-Rust M, Romen D, Vermehren J, Kriener S, Sadet D, Herrmann E, Zeuzem S, Bojunga J. Acoustic radiation force impulse-imaging and transient elastography for non-invasive assessment of liver fibrosis and steatosis in NAFLD. *Eur J Radiol* 2012;81:e325–e331.
- Garcovich M, Veraldi S, Di Stasio E, Zocco MA, Monti L, Toma P, Pompili M, Gasbarrini A, Nobili V. Liver stiffness in pediatric patients with fatty liver disease: Diagnostic accuracy and reproducibility of shear-wave elastography. *Radiology* 2017;283:820–827.
- Gelsi E, Dainese R, Truchi R, Marine-Barjoan E, Anty R, Autuori M, Burroni S, Vanbiervliet G, Evesque L, Cherikh F, Tran A. Effect of detoxification on liver stiffness assessed by Fibroscan® in alcoholic patients. *Alcohol Clin Exp Res* 2011;35:566–570.
- Gersak MM, Sorantin E, Windhaber J, Duda SM, Riccabona M. The influence of acute physical effort on liver stiffness estimation using Virtual Touch quantification (VTQ): Preliminary results. *Med Ultrasonogr* 2016;18:151–156.
- Ghaffar TA, Youssef A, Zalata K, ElSharkawy A, Mowafy M, Wanis AAA, Esmat G. Noninvasive assessment of liver fibrosis in Egyptian children with chronic liver diseases. *Curr Pediatr Res* 2016;20:53–63.
- Gianni E, Forte P, Galli V, Razzolini G, Bardazzi G, Annese V. Prospective evaluation of liver stiffness using transient elastography in alcoholic patients following abstinence. *Alcohol Alcohol* 2017;52:42–47.
- Goldschmidt I, Streckenbach C, Dingemann C, Pfister ED, di Nanni A, Zapf A, Baumann U. Application and limitations of transient liver elastography in children. *J Pediatr Gastroenterol Nutr* 2013;57:109–113.
- Grgurevic I, Bokun T, Mustapic S, Trkulja V, Heinzl R, Banic M, Puljiz Z, Luksic B, Kujundzic M. Real-time two-dimensional shear wave ultrasound elastography of the liver is a reliable predictor of clinical outcomes and the presence of esophageal varices in patients with compensated liver cirrhosis. *Croat Med J* 2015;56:470–481.
- Guo L, Zheng L, Hu L, Zhou H, Yu L, Liang W. Transient elastography (FibroScan) performs better than non-invasive markers in

- assessing liver fibrosis and cirrhosis in autoimmune hepatitis patients. *Med Sci Monit* 2017;23:5106–5112.
- Hall TJ, Milkowski A, Garra B, Carson P, Palmeri M, Nightingale K, Lynch T, Alturki A, Andre M, Audiere S, Bamber J, Barr R, Bercoff J, Bercoff J, Bernal M, Brum J, Chan HW, Chen S, Cohen-Bacrie C, Couade M, Daniels A, DeWall R, Dillman J, Ehrman R, Franchi-Abella SF, Fromageau J, Gennisson JL, Henry JP, Ivancevich N, Kalin J, Kohn S, Kugel J, Lee K, Liu NL, Loupas T, Mazenik J, McAleavey S, Miette V, Metz S, Morel BM, Nelson T, Nordberg E, Oudry J, Padwal M, Rouze N, Samir A, Sandrin L, Schaccitti J, Schmitt C, Shamdasani V, Song P, Wang M, Wear K, Xie H, Zhao H. RSNA/QIBA: Shear wave speed as a biomarker for liver fibrosis staging. *Proc IEEE Int Ultrason Symp.* 2013;397–400.
- Hanquinet S, Courvoisier D, Kanavaki A, Dhoub A, Anooshiravani M. Acoustic radiation force impulse imaging-normal values of liver stiffness in healthy children. *Pediatr Radiol* 2013;43:539–544.
- Hanquinet S, Courvoisier DS, Rougemont AL, Dhoub A, Rubbia-Brandt L, Wildhaber BE, Merlini L, McLin VA, Anooshiravani M. Contribution of acoustic radiation force impulse (ARFI) elastography to the ultrasound diagnosis of biliary atresia. *Pediatr Radiol* 2015;45:1489–1495.
- Hanquinet S, Courvoisier DS, Rougemont AL, Wildhaber BE, Merlini L, McLin VA, Anooshiravani M. Acoustic radiation force impulse sonography in assessing children with biliary atresia for liver transplantation. *Pediatr Radiol* 2016;46:1011–1016.
- Hartl J, Denzer U, Ehlsen H, Zenouzi R, Peiseler M, Sebode M, Hubener S, Pannicke N, Weiler-Normann C, Quaas A, Lohse AW, Schramm C. Transient elastography in autoimmune hepatitis: Timing determines the impact of inflammation and fibrosis. *J Hepatol* 2016;65:769–775.
- Hattapoglu S, Goya C, Arslan S, Alan B, Ekici F, Tekbas G, Yildiz I, Hamidi C. Evaluation of postoperative undescended testicles using point shear wave elastography in children. *Ultrasonics* 2016;72:191–194.
- Hennes EM, Zeniya M, Czaja AJ, Pares A, Dalekos GN, Krawitt EL, Bittencourt PL, Porta G, Boberg KM, Hofer H, Bianchi FB, Shibata M, Schramm C, Eisenmann de Torres B, Galle PR, McFarlane I, Dienes HP, Lohse AW. International Autoimmune Hepatitis G. Simplified criteria for the diagnosis of autoimmune hepatitis. *Hepatology* 2008;48:169–176.
- Herrmann E, de Ledinghen V, Cassinotto C, Chu WC, Leung VY, Ferraioli G, Filice C, Castera L, Vilgrain V, Ronot M, Dumortier J, Guibal A, Pol S, Trebicka J, Jansen C, Strassburg C, Zheng R, Zheng J, Francque S, Vanwolleghem T, Vonghia L, Manesis EK, Zoumpoulis P, Sporea I, Thiele M, Krag A, Cohen-Bacrie C, Criton A, Gay J, Deffieux T, Friedrich-Rust M. Assessment of biopsy-proven liver fibrosis by two-dimensional shear wave elastography: An individual patient data-based meta-analysis. *Hepatology* 2018;67:260–272.
- Hezode C, Castera L, Roudot-Thoraval F, Bouvier-Alias M, Rosa I, Roulot D, Leroy V, Mallat A, Pawlowsky JM. Liver stiffness diminishes with antiviral response in chronic hepatitis C. *Aliment Pharmacol Ther* 2011;34:656–663.
- Hu X, Qiu L, Liu D, Qian L. Acoustic radiation force impulse (ARFI) elastography for noninvasive evaluation of hepatic fibrosis in chronic hepatitis B and C patients: A systematic review and meta-analysis. *Med Ultrason* 2017;19:23–31.
- Hudson JM, Milot L, Parry C, Williams R, Burns PN. Inter- and intra-operator reliability and repeatability of shear wave elastography in the liver: A study in healthy volunteers. *Ultrasound Med Biol* 2013;39:950–955.
- Imajo K, Kessoku T, Honda Y, Tomeno W, Ogawa Y, Mawatari H, Fujita K, Yoneda M, Taguri M, Hyogo H, Sumida Y, Ono M, Eguchi Y, Inoue T, Yamanaka T, Wada K, Saito S, Nakajima A. Magnetic resonance imaging more accurately classifies steatosis and fibrosis in patients with nonalcoholic fatty liver disease than transient elastography. *Gastroenterology* 2016;150:626–637.e627.
- Jansen C, Bogs C, Verlinden W, Thiele M, Moller P, Gortzen J, Lehmann J, Praktijnjo M, Chang J, Krag A, Strassburg CP, Francque S, Trebicka J. Algorithm to rule out clinically significant portal hypertension combining shear-wave elastography of liver and spleen: A prospective multicentre study. *Gut* 2016a;65:1057–1058.
- Jansen C, Bogs C, Verlinden W, Thiele M, Moller P, Gortzen J, Lehmann J, Vanwolleghem T, Vonghia L, Praktijnjo M, Chang J, Krag A, Strassburg CP, Francque S, Trebicka J. Shear-wave elastography of the liver and spleen identifies clinically significant portal hypertension: A prospective multicentre study. *Liver Int* 2016b;37:396–405.
- Janssens F, de Suray N, Piessevaux H, Horsmans Y, de Timary P, Starckel P. Can transient elastography replace liver histology for determination of advanced fibrosis in alcoholic patients: A real-life study. *J Clin Gastroenterol* 2010;44:575–582.
- Jung C, Groth M, Petersen KU, Hammel A, Brinkert F, Grabhorn E, Weidemann SA, Busch J, Adam G, Herrmann J. Hepatic shear wave elastography in children under free-breathing and breath-hold conditions. *Eur Radiol* 2017;27:5337–5343.
- Jung KS, Kim BK, Kim SU, Chon YE, Chun KH, Kim SB, Lee SH, Ahn SS, Park JY, Kim DY, Ahn SH, Park YN, Han KH. Factors affecting the accuracy of controlled attenuation parameter (CAP) in assessing hepatic steatosis in patients with chronic liver disease. *PLoS One* 2014;9:e98689.
- Kamble R, Sodhi KS, Thapa BR, Saxena AK, Bhatia A, Dayal D, Khandelwal N. Liver acoustic radiation force impulse (ARFI) in childhood obesity: comparison and correlation with biochemical markers. *J Ultrasound* 2017;20:33–42.
- Karlas T, Petroff D, Sasso M, Fan JG, Mi YQ, de Ledinghen V, Kumar M, Lupsor-Platon M, Han KH, Cardoso AC, Ferraioli G, Chan WK, Wong VW, Myers RP, Chayama K, Friedrich-Rust M, Beaugrand M, Shen F, Hiriart JB, Sarin SK, Badea R, Jung KS, Marcelin P, Filice C, Mahadeva S, Wong GL, Crotty P, Masaki K, Bojunga J, Bedossa P, Keim V, Wiegand J. Individual patient data meta-analysis of controlled attenuation parameter (CAP) technology for assessing steatosis. *J Hepatol* 2017;66:1022–1030.
- Kiani A, Brun V, Laine F, Turlin B, Morcet J, Michalak S, Le Gruyer A, Legros L, Bardou-Jacquet E, Gandon Y, Moirand R. Acoustic radiation force impulse imaging for assessing liver fibrosis in alcoholic liver disease. *World J Gastroenterol* 2016;22:4926–4935.
- Kim SG, Kim YS, Jung SW, Kim HK, Jang JY, Moon JH, Kim HS, Lee JS, Lee MS, Shim CS, Kim BS. [The usefulness of transient elastography to diagnose cirrhosis in patients with alcoholic liver disease]. *Korean J Hepatol* 2009;15:42–51.
- Kim TY, Jeong WK, Sohn JH, Kim J, Kim MY, Kim Y. Evaluation of portal hypertension by real-time shear wave elastography in cirrhotic patients. *Liver Int* 2015;35:2416–2424.
- Kim MS, Kim BI, Kwon HJ, Park HW, Park HJ, Bang KB, Hong HP, Rho MH. Discordance between conventional ultrasonography and ElastPQ for assessing hepatic fibrosis in chronic hepatitis B: Frequency and independent factors. *J Med Ultrason* 2016;43:201–210.
- Knop V, Hoppe D, Welzel T, Vermehren J, Herrmann E, Vermehren A, Friedrich-Rust M, Sarrazin C, Zeuzem S, Welker MW. Regression of fibrosis and portal hypertension in HCV-associated cirrhosis and sustained virologic response after interferon-free antiviral therapy. *J Viral Hepat* 2016;23:994–1002.
- Kobayashi K, Nakao H, Nishiyama T, Lin Y, Kikuchi S, Kobayashi Y, Yamamoto T, Ishii N, Ohashi T, Satoh K, Nakade Y, Ito K, Yoneda M. Diagnostic accuracy of real-time tissue elastography for the staging of liver fibrosis: A meta-analysis. *Eur Radiol* 2015;25:230–238.
- Kumar M, Rastogi A, Singh T, Behari C, Gupta E, Garg H, Kumar R, Bhatia V, Sarin SK. Controlled attenuation parameter for non-invasive assessment of hepatic steatosis: Does etiology affect performance? *J Gastroenterol Hepatol* 2013;28:1194–1201.
- Lampertico P, Invernizzi F, Vigano M, Loglio A, Mangia G, Facchetti F, Primignani M, Jovani M, Iavarone M, Fraquelli M, Casazza G, de Franchis R, Colombo M. The long-term benefits of nucleos(t)ide analogs in compensated HBV cirrhotic patients with no or small esophageal varices: A 12-year prospective cohort study. *J Hepatol* 2015;63:1118–1125.
- Lannerstedt H, Konopski Z, Sandvik L, Haaland T, Loberg EM, Haukeland JW. Combining transient elastography with FIB4 enhances

- sensitivity in detecting advanced fibrosis of the liver. *Scand J Gastroenterol* 2013;48:93–100.
- Lee CK, Perez-Atayde AR, Mitchell PD, Raza R, Afdhal NH, Jonas MM. Serum biomarkers and transient elastography as predictors of advanced liver fibrosis in a United States cohort: the Boston children's hospital experience. *J Pediatr* 2013;163:1058–1064.e1052.
- Lemoine M, Katsahian S, Zioli M, Nahon P, Ganne-Carrie N, Kazemi F, Grando-Lemaire V, Trinchet JC, Beaugrand M. Liver stiffness measurement as a predictive tool of clinically significant portal hypertension in patients with compensated hepatitis C virus or alcohol-related cirrhosis. *Aliment Pharmacol Ther* 2008;28:1102–1110.
- Lens S, Alvarado E, Marino Z, Londono MC, Llop E, Martinez J, Fortea JJ, Ibanez L, Ariza X, Baiges A, Gallego A, Banares R, Puente A, Albillos A, Calleja JL, Torras X, Hernandez-Gea V, Bosch J, Villanueva C, Forns X, Garcia-Pagan JC. Effects of all-oral antiviral therapy on HVP and systemic hemodynamics in patients with hepatitis C virus-associated cirrhosis. *Gastroenterology* 2017;153:1273–1283.e1.
- Leung VY, Shen J, Wong VW, Abrigo J, Wong GL, Chim AM, Chu SH, Chan AW, Choi PC, Ahuja AT, Chan HL, Chu WC. Quantitative elastography of liver fibrosis and spleen stiffness in chronic hepatitis B carriers: Comparison of shear-wave elastography and transient elastography with liver biopsy correlation. *Radiology* 2013;269:910–918.
- Lewindon PJ, Balouch F, Pereira TN, Puertolas-Lopez MV, Noble C, Wixey JA, Ramm GA. Transient liver elastography in unsedated control children: Impact of age and intercurrent illness. *J Paediatr Child Health* 2016;52:637–642.
- Liang X, Xie Q, Tan D, Ning Q, Niu J, Bai X, Chen S, Cheng J, Yu Y, Wang H, Xu M, Shi G, Wan M, Chen X, Tang H, Sheng J, Dou X, Shi J, Ren H, Wang M, Zhang H, Gao Z, Chen C, Ma H, Chen Y, Fan R, Sun J, Jia J, Hou J. Interpretation of liver stiffness measurement-based approach for the monitoring of hepatitis B patients with antiviral therapy: A 2-year prospective study. *J Viral Hepat* 2018;25:296–305.
- Liu F, Wei L, Tang X, Wang S, Bao J, Zheng Z. [Clinical value of virtual touch tissue quantification and PGA index in evaluation of alcoholic liver fibrosis]. *Zhong Nan Da Xue Xue Bao Yi Xue Ban* 2015a;40:1246–1252.
- Liu H, Fu J, Hong R, Liu L, Li F. Acoustic radiation force impulse elastography for the non-invasive evaluation of hepatic fibrosis in non-alcoholic fatty liver disease patients: A systematic review & meta-analysis. *PloS One* 2015b;10:e0127782.
- Liu K, Wong VW, Lau K, Liu SD, Tse YK, Yip TC, Kwok R, Chan AY, Chan HL, Wong GL. Prognostic value of controlled attenuation parameter by transient elastography. *Am J Gastroenterol* 2017;112:1812–1823.
- Lodwick D, Dienhart M, Cooper JN, Fung B, Lopez J, Smith S, Warren P, Balint J, Minneci PC. A pilot study of ultrasound elastography as a non-invasive method to monitor liver disease in children with short bowel syndrome. *J Pediatr Surg* 2017;52:962–965.
- Ma X, Wang L, Wu H, Feng Y, Han X, Bu H, Zhu Q. Spleen stiffness is superior to liver stiffness for predicting esophageal varices in chronic liver disease: A meta-analysis. *PloS One* 2016;11:e0165786.
- MacSween RN, Burt AD. Histologic spectrum of alcoholic liver disease. *Semin Liver Dis* 1986;6:221–232.
- Mann JP, De Vito R, Mosca A, Alisi A, Armstrong MJ, Raponi M, Baumann U, Nobili V. Portal inflammation is independently associated with fibrosis and metabolic syndrome in pediatric nonalcoholic fatty liver disease. *Hepatology* 2016;63:745–753.
- Manns MP, Czaja AJ, Gorham JD, Krawitt EL, Mieli-Vergani G, Vergani D, Vierling JM. American Association for the Study of Liver Disease. Diagnosis and management of autoimmune hepatitis. *Hepatology* 2010;51:2193–2213.
- Marcellin P, Gane E, Buti M, Afdhal N, Sievert W, Jacobson IM, Washington MK, Germanidis G, Flaherty JF, Schall RA, Bornstein JD, Kittrinos KM, Subramanian GM, McHutchison JG, Heathcote EJ. Regression of cirrhosis during treatment with tenofovir disoproxil fumarate for chronic hepatitis B: A 5-year open-label follow-up study. *Lancet* 2013;381:468–475.
- Marginean CO, Marginean C. Elastographic assessment of liver fibrosis in children: A prospective single center experience. *Eur J Radiol* 2012;81:e870–e874.
- Marot A, Trepo E, Doerig C, Schoepfer A, Moreno C, Deltenre P. Liver stiffness and platelet count for identifying patients with compensated liver disease at low risk of variceal bleeding. *Liver Int* 2017;37:707–716.
- Matos H, Trindade A, Noruegas MJ. Acoustic radiation force impulse imaging in paediatric patients: Normal liver values. *J Pediatr Gastroenterol Nutr* 2014;59:684–688.
- Mueller S, Millonig G, Sarovska L, Friedrich S, Reimann FM, Pritsch M, Eisele S, Stickel F, Longereich T, Schirmacher P, Seitz HK. Increased liver stiffness in alcoholic liver disease: Differentiating fibrosis from steatohepatitis. *World J Gastroenterol* 2010;16:966–972.
- Mueller S, Englert S, Seitz HK, Badea RI, Erhardt A, Bozaari B, Beaugrand M, Lupsor-Platon M. Inflammation-adapted liver stiffness values for improved fibrosis staging in patients with hepatitis C virus and alcoholic liver disease. *Liver Int* 2015;35:2514–2521.
- Myers RP, Pollett A, Kirsch R, Pomier-Layrargues G, Beaton M, Levstik M, Duarte-Rojo A, Wong D, Crotty P, Elkashab M. Controlled attenuation parameter (CAP): A noninvasive method for the detection of hepatic steatosis based on transient elastography. *Liver Int* 2012;32:902–910.
- Nahon P, Kettaneh A, Tengher-Barna I, Zioli M, de Ledinghen V, Douvin C, Marcellin P, Ganne-Carrie N, Trinchet JC, Beaugrand M. Assessment of liver fibrosis using transient elastography in patients with alcoholic liver disease. *J Hepatol* 2008;49:1062–1068.
- Nahon P, Bourcier V, Layese R, Audureau E, Cagnot C, Marcellin P, Guyader D, Fontaine H, Larrey D, De Ledinghen V, Ouzan D, Zoulim F, Roulot D, Tran A, Bronowicki JP, Zarski JP, Leroy V, Riachi G, Cales P, Peron JM, Alric L, Bourliere M, Mathurin P, Dharancy S, Blanc JF, Aberger A, Serfaty L, Mallat A, Grange JD, Attali P, Bacq Y, Wartelle C, Dao T, Benhamou Y, Pilette C, Silvain C, Christidis C, Capron D, Bernard-Chabert B, Zucman D, Di Martino V, Thibaut V, Salmon D, Zioli M, Sutton A, Pol S, Roudot-Thoraval F. ANRS CO12 CirVir Group. Eradication of hepatitis C virus infection in patients with cirrhosis reduces risk of liver and non-liver complications. *Gastroenterology* 2017;152:142–156.e142.
- Nguyen-Khac E, Chatelain D, Tramier B, Decrombecque C, Robert B, Joly JP, Brevet M, Grignon P, Lion S, Le Page L, Dupas JL. Assessment of asymptomatic liver fibrosis in alcoholic patients using fibroscan: Prospective comparison with seven non-invasive laboratory tests. *Aliment Pharmacol Ther* 2008;28:1188–1198.
- O'Shea RS, Dasarthy S, McCullough AJ, Practice Guideline Committee of the American Association for the Study of Liver D, Practice Parameters Committee of the American College of G. Alcoholic liver disease. *Hepatology* 2010;51:307–328.
- Ogasawara N, Kobayashi M, Akuta N, Kominami Y, Fujiyama S, Kawamura Y, Sezaki H, Hosaka T, Suzuki F, Saitoh S, Suzuki Y, Arase Y, Ikeda K, Kobayashi M, Kumada H. Serial changes in liver stiffness and controlled attenuation parameter following direct-acting antiviral therapy against hepatitis C virus genotype 1b. *J Med Virol* 2018;90:313–319.
- Omichi K, Inoue Y, Hasegawa K, Sakamoto Y, Okinaga H, Aoki T, Sugawara Y, Kurahashi I, Kokudo N. Differential diagnosis of liver tumours using intraoperative real-time tissue elastography. *The British journal of surgery* 2015;102:246–253.
- Osaki A, Kubota T, Suda T, Igarashi M, Nagasaki K, Tsuchiya A, Yano M, Tamura Y, Takamura M, Kawai H, Yamagiwa S, Kikuchi T, Nomoto M, Aoyagi Y. Shear wave velocity is a useful marker for managing nonalcoholic steatohepatitis. *World J Gastroenterol* 2010;16:2918–2925.
- Oxford Centre for Evidence-Based Medicine. Levels of evidence. Oxford: University of Oxford, 2009.
- Ozkan MB, Bilgici MC, Eren E, Caltepe G, Yilmaz G, Kara C, Gun S. Role of point shear wave elastography in the determination of the severity of fibrosis in pediatric liver diseases with pathologic correlations. *J Ultrasound Med* 2017;36:2337–2344.

- Palmeri M, Nightingale K, Fielding S, Rouze N, Deng Y, Lynch T, Chen S, Song P, Urban M, Xie H, Wear K, Garra B, Milkowski A, Rosenzweig S, Carson P, Barr R, Shamdasani V, Macdonald M, Wang M, Guenette G, Miyajima Y, Okamura Y, Dhyani M, Samir A, Hah Z, McLaughlin G, Gee A, Chen Y, Napolitano D, McAleavey S, Obuchowski N, Hall T. RSNA QIBA ultrasound shear wave speed phase II phantom study in viscoelastic media. *Proc IEEE Int Ultrason Symp* 2015;1–4.
- Park CC, Nguyen P, Hernandez C, Bettencourt R, Ramirez K, Fortney L, Hooker J, Sy E, Savides MT, Alquraish MH, Valasek MA, Rizo E, Richards L, Brenner D, Sirlin CB, Loomba R. Magnetic resonance elastography vs transient elastography in detection of fibrosis and noninvasive measurement of steatosis in patients with biopsy-proven nonalcoholic fatty liver disease. *Gastroenterology* 2017;152:598–607.e592.
- Pavlov CS, Casazza G, Nikolova D, Tsochatzis E, Burroughs AK, Ivashkin VT, Gluud C. Transient elastography for diagnosis of stages of hepatic fibrosis and cirrhosis in people with alcoholic liver disease. *Cochrane Database Syst Rev* 2015;1:CD010542.
- Pavlov CS, Casazza G, Nikolova D, Tsochatzis E, Gluud C. Systematic review with meta-analysis: Diagnostic accuracy of transient elastography for staging of fibrosis in people with alcoholic liver disease. *Aliment Pharmacol Ther* 2016;43:575–585.
- Persico M, Rosato V, Aglitti A, Precone D, Corrado M, De Luna A, Morisco F, Camera S, Federico A, Dallio M, Claar E, Caporaso N, Masarone M. Sustained virological response by direct antiviral agents in HCV leads to an early and significant improvement of liver fibrosis. *Antivir Ther* 2018;23:129–138.
- Petta S, Vanni E, Bugianesi E, Di Marco V, Camma C, Cabibi D, Mezzabotta L, Craxi A. The combination of liver stiffness measurement and NAFLD fibrosis score improves the noninvasive diagnostic accuracy for severe liver fibrosis in patients with nonalcoholic fatty liver disease. *Liver Int* 2015;35:1566–1573.
- Petta S, Wong VW, Camma C, Hiriart JB, Wong GL, Marra F, Vergnion J, Chan AW, Di Marco V, Merrouche W, Chan HL, Barbara M, Le-Bail B, Arena U, Craxi A, de Ledinghen V. Improved noninvasive prediction of liver fibrosis by liver stiffness measurement in patients with nonalcoholic fatty liver disease accounting for controlled attenuation parameter values. *Hepatology* 2017;65:1145–1155.
- Phelps A, Ramachandran R, Courtier J, Perito E, Rosenthal P, MacKenzie JD. Ultrasound elastography: is there a shear wave speed cut-off for pediatric liver fibrosis and inflammation? *Clin Imaging* 2017;41:95–100.
- Pineda JA, Recio E, Camacho A, Macias J, Almodovar C, Gonzalez-Serrano M, Merino D, Tellez F, Rios MJ, Rivero A. Grupo Andaluz de Hepatitis Virica de la Sociedad Andaluza de Enfermedades I. Liver stiffness as a predictor of esophageal varices requiring therapy in HIV/hepatitis C virus-coinfected patients with cirrhosis. *J Acquired Immune Defic Syndr* 2009;51:445–449.
- Pinto J, Matos H, Nobre S, Cipriano MA, Marques M, Pereira JM, Goncalves I, Noruegas MJ. Comparison of acoustic radiation force impulse/serum noninvasive markers for fibrosis prediction in liver transplant. *J Pediatr Gastroenterol Nutr* 2014;58:382–386.
- Piscaglia F, Salvatore V, Mulazzani L, Cantisani V, Colecchia A, Di Donato R, Felicani C, Ferrarini A, Gamal N, Grasso V, Marasco G, Mazzotta E, Ravaoli F, Ruggieri G, Serio I, Sitouok Nkamgho JF, Serra C, Festi D, Schiavone C, Bolondi L. Differences in liver stiffness values obtained with new ultrasound elastography machines and Fibroscan: A comparative study. *Dig Liver Dis* 2017;49:802–808.
- Pons M, Santos B, Simon-Talero M, Ventura-Cots M, Riveiro-Barciela M, Esteban R, Augustin S, Genesca J. Rapid liver and spleen stiffness improvement in compensated advanced chronic liver disease patients treated with oral antivirals. *Ther Adv Gastroenterol* 2017;10:619–629.
- Potthoff A, Attia D, Pischke S, Kirschner J, Mederacke I, Wedemeyer H, Manns MP, Gebel MJ, Rifai K. Influence of different frequencies and insertion depths on the diagnostic accuracy of liver elastography by acoustic radiation force impulse imaging (ARFI). *Eur J Radiol* 2013;82:1207–1212.
- Price JC, Dodge JL, Ma Y, Scherzer R, Korn N, Tillinghast K, Peters MG, Noworolski S, Tien PC. Controlled attenuation parameter and magnetic resonance spectroscopy-measured liver steatosis are discordant in obese HIV-infected adults. *AIDS* 2017;31:2119–2125.
- Procopet B, Berzigotti A, Abrandes JG, Turon F, Hernandez-Gea V, Garcia-Pagan JC, Bosch J. Real-time shear-wave elastography: Applicability, reliability and accuracy for clinically significant portal hypertension. *J Hepatol* 2015;62:1068–1075.
- Raizner A, Shillingford N, Mitchell PD, Harney S, Raza R, Serino J, Jonas MM, Lee CK. Hepatic inflammation may influence liver stiffness measurements by transient elastography in children and young adults. *J Pediatr Gastroenterol Nutr* 2017;64:512–517.
- Recio E, Cifuentes C, Macias J, Mira JA, Parra-Sanchez M, Rivero-Juarez A, Almeida C, Pineda JA, Neukam K. Interobserver concordance in controlled attenuation parameter measurement, a novel tool for the assessment of hepatic steatosis on the basis of transient elastography. *Eur J Gastroenterol Hepatol* 2013;25:905–911.
- Reiberger T, Ferlitsch A, Payer BA, Pinter M, Homoncik M, Peck-Radosavljevic M. Vienna Hepatic Hemodynamic Lab. Non-selective beta-blockers improve the correlation of liver stiffness and portal pressure in advanced cirrhosis. *J Gastroenterol* 2012;47:561–568.
- Righi S, Fiorini E, De Molo C, Cipriano V, Cassani F, Muratori L, Lenzi M, Morselli Labate AM, Serra C. ARFI elastography in patients with chronic autoimmune liver diseases: A preliminary study. *J Ultrasound* 2012;15:226–231.
- Robic MA, Procopet B, Metivier S, Peron JM, Selves J, Vinel JP, Bureau C. Liver stiffness accurately predicts portal hypertension related complications in patients with chronic liver disease: A prospective study. *J Hepatol* 2011;55:1017–1024.
- Runge JH, Smits LP, Verheij J, Depla A, Kuiken SD, Baak BC, Nederveen AJ, Beuers U, Stoker J. MR spectroscopy-derived proton density fat fraction is superior to controlled attenuation parameter for detecting and grading hepatic steatosis. *Radiology* 2017;286:547–556.
- Sagir A, Erhardt A, Schmitt M, Haussinger D. Transient elastography is unreliable for detection of cirrhosis in patients with acute liver damage. *Hepatology* 2008;47:592–595.
- Salz P, Reiberger T, Ferlitsch M, Payer BA, Schwengerer B, Trauner M, Peck-Radosavljevic M, Ferlitsch A. Evaluation of portal hypertension and varices by acoustic radiation force impulse imaging of the liver compared to transient elastography and AST to platelet ratio index. *Ultraschall Med* 2014;35:528–533.
- Sasso M, Beaugrand M, de Ledinghen V, Douvin C, Marcellin P, Poupon R, Sandrin L, Miette V. Controlled attenuation parameter (CAP): A novel VCTE guided ultrasonic attenuation measurement for the evaluation of hepatic steatosis: Preliminary study and validation in a cohort of patients with chronic liver disease from various causes. *Ultrasound Med Biol* 2010;36:1825–1835.
- Sasso M, Tengher-Barna I, Zioli M, Miette V, Fournier C, Sandrin L, Poupon R, Cardoso AC, Marcellin P, Douvin C, de Ledinghen V, Trinchet JC, Beaugrand M. Novel controlled attenuation parameter for noninvasive assessment of steatosis using Fibroscan(R): validation in chronic hepatitis C. *J Viral Hepatitis* 2012;19:244–253.
- Schenk JP, Alzen G, Klingmuller V, Teufel U, El Sakka S, Engelmann G, Selmi B. Measurement of real-time tissue elastography in a phantom model and comparison with transient elastography in pediatric patients with liver diseases. *Diagn Interv Radiol* 2014a;20:90–99.
- Schenk JP, Selmi B, Flechtenmacher C, Sakka SE, Teufel U, Engelmann G. Real-time tissue elastography (RTE) for noninvasive evaluation of fibrosis in liver diseases in children in comparison to liver biopsy. *J Med Ultrason* 2014b;41:455–462.
- Selmi B, Engelmann G, Teufel U, El Sakka S, Dadrach M, Schenk JP. Normal values of liver elasticity measured by real-time tissue elastography (RTE) in healthy infants and children. *J Med Ultrason* 2014b;41:31–38.
- Shiina T, Nightingale KR, Palmeri ML, Hall TJ, Bamber JC, Barr RG, Castera L, Choi BI, Chou YH, Cosgrove D, Dietrich CF, Ding H, Amy D, Farrokh A, Ferraioli G, Filice C, Friedrich-Rust M, Nakashima K, Schafer F, Sporea I, Suzuki S, Wilson S, Kudo M. WFUMB guidelines and recommendations for clinical use of

- ultrasound elastography: Part 1. Basic principles and terminology. *Ultrasound Med Biol* 2015;41:1126–1147.
- Shin HJ, Kim MJ, Kim HY, Roh YH, Lee MJ. Optimal acquisition number for hepatic shear wave velocity measurements in children. *PLoS One* 2016;11:e0168758.
- Sigrist RMS, Liau J, Kaffas AE, Chammas MC, Willmann JK. Ultrasound elastography: Review of techniques and clinical applications. *Theranostics* 2017;7:1303–1329.
- Singh S, Fujii LL, Murad MH, Wang Z, Asrani SK, Ehman RL, Kamath PS, Talwalkar JA. Liver stiffness is associated with risk of decompensation, liver cancer, and death in patients with chronic liver diseases: A systematic review and meta-analysis. *Clin Gastroenterol Hepatol* 2013;11:1573–1584.e2.
- Sporea I, Bota S, Jurchis A, Sirli R, Gradinaru-Tascasu O, Popescu A, Ratiu I, Szilaski M. Acoustic radiation force impulse and super-sonic shear imaging versus transient elastography for liver fibrosis assessment. *Ultrasound Med Biol* 2013;39:1933–1941.
- Sporea I, Lupusoru R, Mare R, Popescu A, Gheorghe L, Iacob S, Sirli R. Dynamics of liver stiffness values by means of transient elastography in patients with HCV liver cirrhosis undergoing interferon free treatment. *J Gastrointest Liver Dis* 2017;26:145–150.
- Stewart S, Day C. Alcohol and the liver. In: Dooley JS, Lok A, Burroughs AK, Heathcote J, (eds). *Sherlock's diseases of the liver and biliary system*. 12th edition Oxford/New York: Wiley-Blackwell; 2011. p. 507–520.
- Su TH, Liao CH, Liu CH, Huang KW, Tseng TC, Yang HC, Liu CJ, Chen PJ, Chen DS, Kao JH. Acoustic radiation force impulse US imaging: Liver stiffness in patients with chronic hepatitis B with and without antiviral therapy. *Radiology* 2018;288:293–299.
- Sun LL, Chang W, Jiao LQ, Cui X, Dong G. Hepatic fibrosis and super-sonic shear imaging in patients with different etiological chronic hepatic diseases. *J Biol Regul Homeost Agents* 2016;30:761–765.
- Takuma Y, Nouse K, Morimoto Y, Tomokuni J, Sahara A, Toshikuni N, Takabatake H, Shimomura H, Doi A, Sakakibara I, Matsueda K, Yamamoto H. Measurement of spleen stiffness by acoustic radiation force impulse imaging identifies cirrhotic patients with esophageal varices. *Gastroenterology* 2013;144:92–101 e102.
- Takuma Y, Nouse K, Morimoto Y, Tomokuni J, Sahara A, Takabatake H, Doi A, Matsueda K, Yamamoto H. Prediction of oesophageal variceal bleeding by measuring spleen stiffness in patients with liver cirrhosis. *Gut* 2016;65:354–355.
- Takuma Y, Nouse K, Morimoto Y, Tomokuni J, Sahara A, Takabatake H, Matsueda K, Yamamoto H. Portal hypertension in patients with liver cirrhosis: Diagnostic accuracy of spleen stiffness. *Radiology* 2016;279:609–619.
- Terrault NA, Lok ASF, McMahon BJ, Chang KM, Hwang JP, Jonas MM, Jr Brown RS, Bzowej NH, Wong JB. Update on prevention, diagnosis, and treatment of chronic hepatitis B: AASLD 2018 hepatitis B guidance. *Hepatology* 2018;67:1560–1599.
- Thiele M, Detlefsen S, Sevelsted Moller L, Madsen BS, Fuglsang Hansen J, Fiialla AD, Trebicka J, Krag A. Transient and 2-dimensional shear-wave elastography provide comparable assessment of alcoholic liver fibrosis and cirrhosis. *Gastroenterology* 2016;150:123–133.
- Thiele M, Madsen BS, Hansen JF, Detlefsen S, Antonsen S, Krag A. Accuracy of the enhanced liver fibrosis test vs fibrotest, elastography and indirect markers in detection of advanced fibrosis in patients with alcoholic liver disease. *Gastroenterology* 2018;154:1369–1379.
- Tokuhara D, Cho Y, Shintaku H. Transient elastography-based liver stiffness age-dependently increases in children. *PLoS One* 2016;11:e0166683.
- Tomita H, Hoshino K, Fuchimoto Y, Ebinuma H, Ohkuma K, Tanami Y, Du W, Masugi Y, Shimojima N, Fujino A, Kano M, Fujimura T, Ishihama H, Shimizu T, Tanabe M, Saito H, Sakamoto M, Hibi T, Kitagawa Y, Kuroda T. Acoustic radiation force impulse imaging for assessing graft fibrosis after pediatric living donor liver transplantation: A pilot study. *Liver Transplant* 2013;19:1202–1213.
- Trabut JB, Thepot V, Nalpas B, Lavielle B, Cosconea S, Corouge M, Vallet-Pichard A, Fontaine H, Mallet V, Sogni P, Pol S. Rapid decline of liver stiffness following alcohol withdrawal in heavy drinkers. *Alcohol Clin Exp Res* 2012;36:1407–1411.
- Trout AT, Dillman JR, Xanthakos S, Kohli R, Sprague G, Serai S, Mahley AD, Podberesky DJ. Prospective assessment of correlation between US acoustic radiation force impulse and MR elastography in a pediatric population: Dispersion of US shear-wave speed measurement matters. *Radiology* 2016;281:544–552.
- van der Meer AJ, Feld JJ, Hofer H, Almasio PL, Calvaruso V, Fernandez-Rodriguez CM, Aleman S, Ganne-Carrie N, D'Ambrosio R, Pol S, Trapero-Marugan M, Maan R, Moreno-Otero R, Mallet V, Hultcrantz R, Weiland O, Rutter K, Di Marco V, Alonso S, Bruno S, Colombo M, de Knegt RJ, Veldt BJ, Hansen BE, Janssen HL. Risk of cirrhosis-related complications in patients with advanced fibrosis following hepatitis C virus eradication. *J Hepatol* 2017;66:485–493.
- Voican CS, Louvet A, Traubt JB, Njike-Nakseu M, Dharancy S, Sanchez A, Corouge M, Lamouri K, Lebrun A, Balian A, Prevot S, Lachgar M, Maitre S, Agostini H, Mathurin P, Perlemuter G, Naveau S. Transient elastography alone and in combination with FibroTest® for the diagnosis of hepatic fibrosis in alcoholic liver disease. *Liver Int* 2017;37:1697–1705.
- Vuppalanchi R, Siddiqui MS, Van Natta ML, Hallinan E, Brandman D, Kowdley K, Neuschwander-Tetri BA, Loomba R, Dasarathy S, Abdelmalek M, Doo E, Tonascia JA, Kleiner DE, Sanyal AJ, Chalasani N, for the NASH Clinical Research Network. Performance characteristics of vibration-controlled transient elastography for evaluation of non-alcoholic fatty liver disease. *Hepatology* 2018;67:134–144.
- Wang QX, Shen L, Qiu DK, Bao H, Chen XY, Zeng MD, Mao YM, Ma X. [Validation of transient elastography (Fibroscan) in assessment of hepatic fibrosis in autoimmune hepatitis]. *Zhonghua gan zang bing za zhi = Zhonghua ganzangbing zazhi = Chin J Hepatol* 2011;19:782–784.
- Wong VW, Wong GL, Chim AM, Choi PC, Chan AW, Tsang SW, Hui AY, Chan HY, Sung JJ, Chan HL. Surrogate end points and long-term outcome in patients with chronic hepatitis B. *Clin Gastroenterol Hepatol* 2009;7:1113–1120.
- Wong VW, Vergniol J, Wong GL, Foucher J, Chan HL, Le Bail B, Choi PC, Kowo M, Chan AW, Merrouche W, Sung JJ, de Ledinghen V. Diagnosis of fibrosis and cirrhosis using liver stiffness measurement in nonalcoholic fatty liver disease. *Hepatology* 2010;51:454–462.
- Wong GL, Wong VW, Choi PC, Chan AW, Chim AM, Yiu KK, Chu SH, Chan FK, Sung JJ, Chan HL. On-treatment monitoring of liver fibrosis with transient elastography in chronic hepatitis B patients. *Antivir Ther* 2011;16:165–172.
- Wong VW, Vergniol J, Wong GL, Foucher J, Chan AW, Chermak F, Choi PC, Merrouche W, Chu SH, Pesque S, Chan HL, de Ledinghen V. Liver stiffness measurement using XL probe in patients with nonalcoholic fatty liver disease. *Am J Gastroenterol* 2012;107:1862–1871.
- Wong GL, Chan HL, Chan HY, Tse PC, Tse YK, Mak CW, Lee SK, Ip ZM, Lam AT, Iu HW, Leung JM, Wong VW. Accuracy of risk scores for patients with chronic hepatitis B receiving entecavir treatment. *Gastroenterology* 2013;144:933–944.
- Wong VW, Petta S, Hiriart JB, Camma C, Wong GL, Marra F, Vergniol J, Chan AW, Tuttolomondo A, Merrouche W, Chan HL, Le Bail B, Arena U, Craxi A, de Ledinghen V. Validity criteria for the diagnosis of fatty liver by M probe-based controlled attenuation parameter. *J Hepatol* 2017;67:577–584.
- Woo H, Lee JY, Yoon JH, Kim W, Cho B, Choi BI. Comparison of the reliability of acoustic radiation force impulse imaging and super-sonic shear imaging in measurement of liver stiffness. *Radiology* 2015;277:881–886.
- Xiao G, Zhu S, Xiao X, Yan L, Yang J, Wu G. Comparison of laboratory tests, ultrasound, or magnetic resonance elastography to detect fibrosis in patients with nonalcoholic fatty liver disease: A meta-analysis. *Hepatology* 2017;66:1486–1501.
- Xu L, Lu W, Li P, Shen F, Mi YQ, Fan JG. A comparison of hepatic steatosis index, controlled attenuation parameter and ultrasound as

- noninvasive diagnostic tools for steatosis in chronic hepatitis B. *Dig Liver Dis* 2017;49:910–917.
- Xu Q, Sheng L, Bao H, Chen X, Guo C, Li H, Ma X, Qiu D, Hua J. Evaluation of transient elastography in assessing liver fibrosis in patients with autoimmune hepatitis. *J Gastroenterol Hepatol* 2017;32:639–644.
- Yada N, Sakurai T, Minami T, Arizumi T, Takita M, Inoue T, Hagiwara S, Ueshima K, Nishida N, Kudo M. Ultrasound elastography correlates treatment response by antiviral therapy in patients with chronic hepatitis C. *Oncology* 2014;87(Suppl 1):118–123.
- Yada N, Sakurai T, Minami T, Arizumi T, Takita M, Hagiwara S, Ida H, Ueshima K, Nishida N, Kudo M. Prospective risk analysis of hepatocellular carcinoma in patients with chronic hepatitis C by ultrasound strain elastography. *Dig Dis* 2016;34:650–653.
- Yada N1, Tamaki N, Koizumi Y, Hirooka M, Nakashima O, Hiasa Y, Izumi N, Kudo M. Diagnosis of fibrosis and activity by a combined use of strain and shear wave imaging in patients with liver disease. *Dig Dis* 2017a;35(6):515–520. <https://doi.org/10.1159/000480140>.
- Yada N1, Sakurai T, Minami T, Arizumi T, Takita M, Hagiwara S, Ida H, Ueshima K, Nishida N, Kudo M. Influence of liver inflammation on liver stiffness measurement in patients with autoimmune hepatitis evaluation by combinational elastography. *Oncology* 2017b;92(Suppl 1):10–15. <https://doi.org/10.1159/000451011>.
- Yoneda M, Suzuki K, Kato S, Fujita K, Nozaki Y, Hosono K, Saito S, Nakajima A. Nonalcoholic fatty liver disease: US-based acoustic radiation force impulse elastography. *Radiology* 2010;256:640–647.
- Yoon HM, Kim SY, Kim KM, Oh SH, Ko GY, Park Y, Lee JS, Jung AY, Cho YA. Liver stiffness measured by shear-wave elastography for evaluating intrahepatic portal hypertension in children. *J Pediatr Gastroenterol Nutr* 2017;64:892–897.
- You MW, Kim KW, Pyo J, Huh J, Kim HJ, Lee SJ, Park SH. A meta-analysis for the diagnostic performance of transient elastography for clinically significant portal hypertension. *Ultrasound Med Biol* 2017;43:59–68.
- Yu H, Wilson SR. Differentiation of benign from malignant liver masses with Acoustic Radiation Force Impulse technique. *Ultrasound Q* 2011;27:217–223.
- Zeng J, Zheng J, Huang Z, Chen S, Liu J, Wu T, Zheng R, Lu M. Comparison of 2-D shear wave elastography and transient elastography for assessing liver fibrosis in chronic hepatitis B. *Ultrasound Med Biol* 2017;43:1563–1570.
- Zhang D, Li P, Chen M, Liu L, Liu Y, Zhao Y, Wang R. Non-invasive assessment of liver fibrosis in patients with alcoholic liver disease using acoustic radiation force impulse elastography. *Abdom Imaging* 2015;40:723–729.
- Zheng J, Guo H, Zeng J, Huang Z, Zheng B, Ren J, Xu E, Li K, Zheng R. Two-dimensional shear-wave elastography and conventional US: The optimal evaluation of liver fibrosis and cirrhosis. *Radiology* 2015;275:290–300.
- Zyklus R, Jonaitis L, Petrenkiene V, Pranculis A, Kupcinskis L. Liver and spleen transient elastography predicts portal hypertension in patients with chronic liver disease: A prospective cohort study. *BMC Gastroenterol* 2015;15:183.